The Digestive System

The human digestive system is an extended tube with specialized parts between two openings, the mouth and the anus.

Digestion takes place within a tube called the digestive tract, which begins with the mouth and ends with the anus. The functions of the digestive system are to ingest food, digest it to nutrients that can cross plasma membranes, absorb nutrients, and eliminate undigestible remains.

The Mouth

- The mouth, which receives food, is bounded externally by the lips and cheeks. The lips extend from the base of the nose to the start of the chin. The red portion of the lips is poorly keratinized, and this allows blood to show through. Most people enjoy eating food largely because they like its texture and taste. Sensory receptors called taste buds occur primarily on the tongue, and when these are activated by the presence of food, nerve impulses travel by way of cranial nerves to the brain.
- The tongue is composed of skeletal muscle whose contraction changes the shape of the tongue. Muscles exterior to the tongue cause it to move about. Fold of mucous membrane on the underside of the tongue attaches it to the floor of the oral cavity. The roof of the mouth separates the nasal cavities from the oral cavity. The roof has two parts:

an anterior (toward the front) **hard palate** and a posterior (toward the back) **soft palate**. The hard palate contains several bones, but the soft palate is composed entirely of muscle. The soft palate ends in a finger-shaped projection called the **uvula**. The tonsils are in the back of the mouth, on either side of the tongue and in the naso pharynx (called adenoids).
The tonsils help protect the body against infections. Three pairs of **salivary glands** send juices (saliva) by way of ducts to the mouth.
Salivary glands have ducts that open on the inner surface of the cheek at the location of the second upper molar. Another pair of salivary glands lies beneath the tongue, and still another pair lies beneath the floor of the oral cavity. The ducts from these salivary glands open under the tongue.
. Saliva contains an enzyme called **salivary amylase** that begins the process of digesting starch.

stive system
eviews both
pular diges-
n accessory
le in diges-
y, we recog-

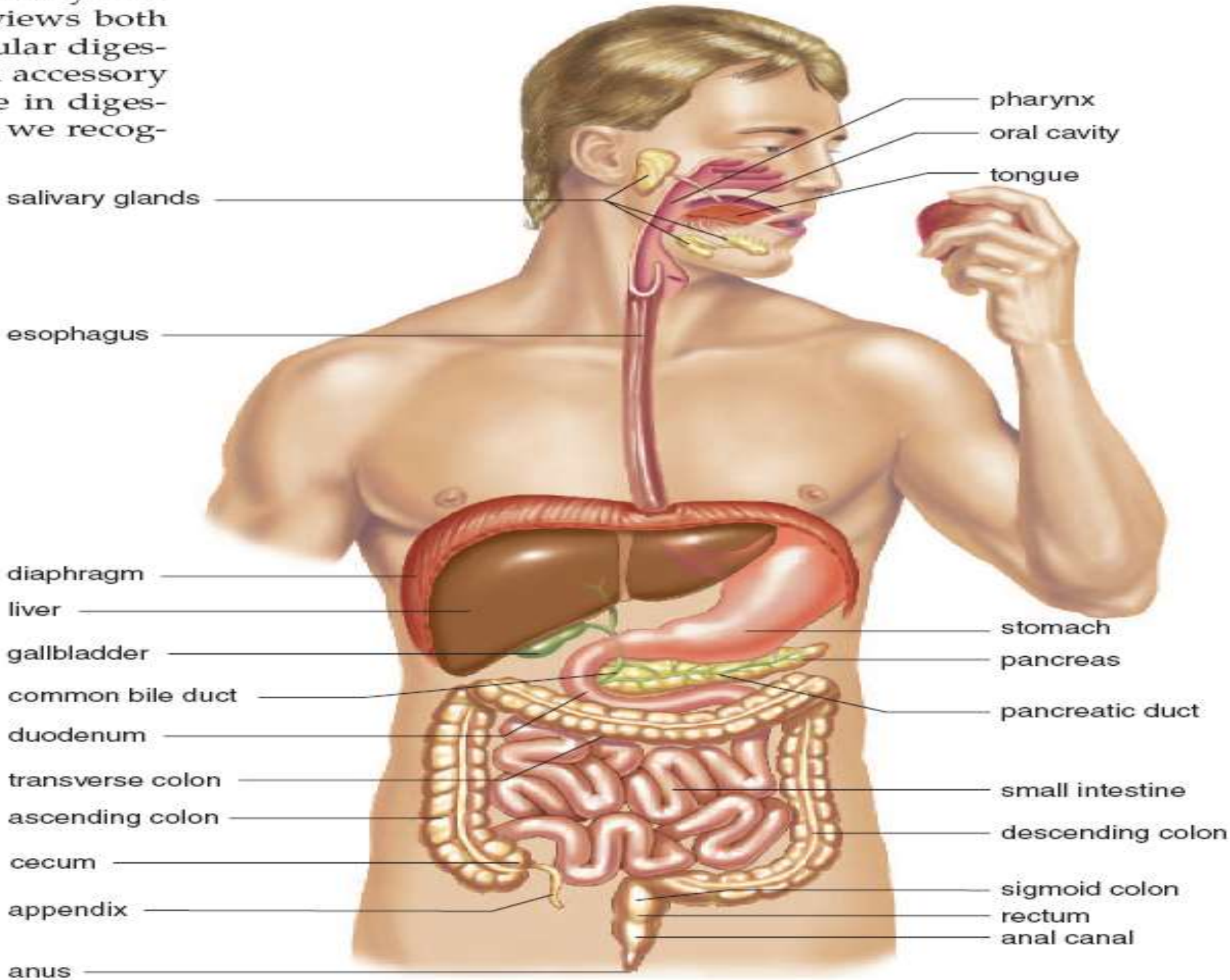

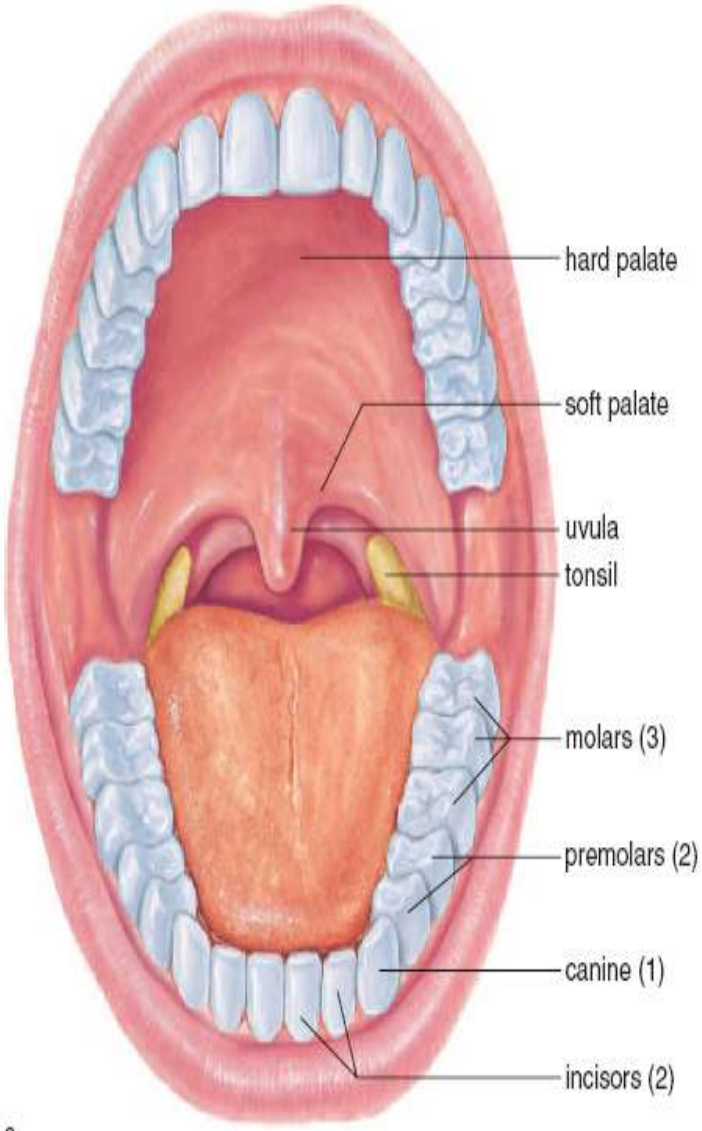
hard palate
soft palate
uvula
tonsil
molars (3)
premolars (2)
canine (1)
incisors (2)

a.

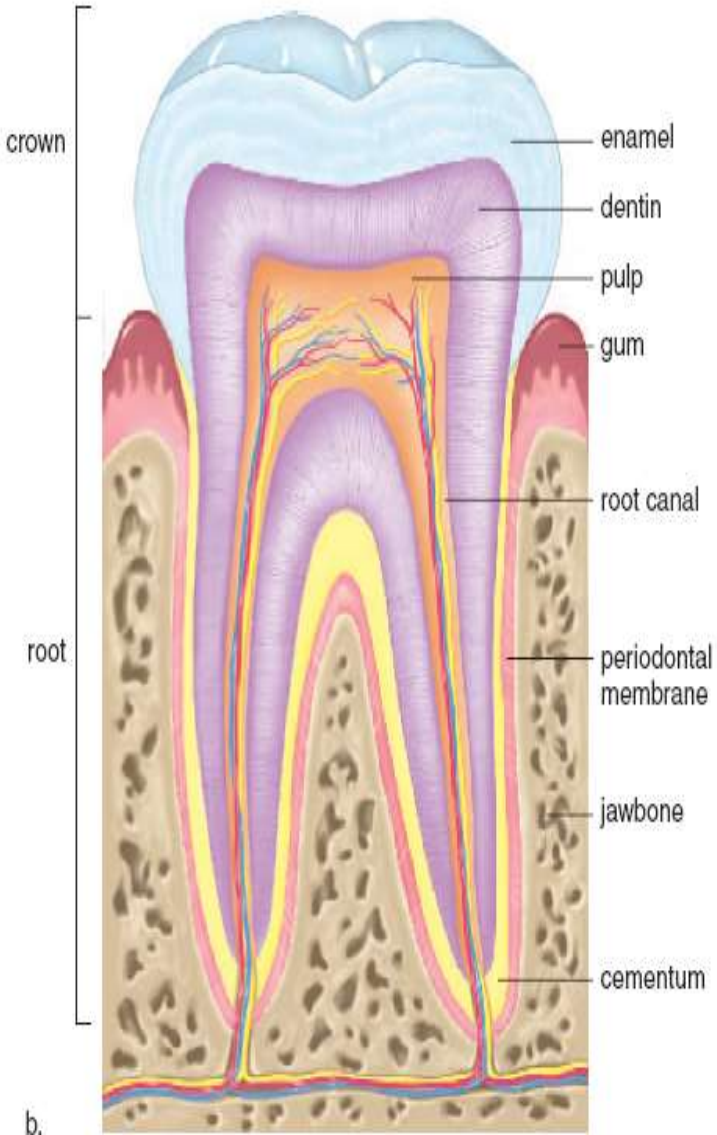
crown
root
enamel
dentin
pulp
gum
root canal
periodontal membrane
jawbone
cementum

b.

The Teeth: With our teeth we chew food into pieces convenient for swallowing. During the first two years of life, the smaller 20 deciduous, or baby, teeth appear.
These are eventually replaced by 32 adult teeth .
The third pair of molars, called the wisdom teeth, sometimes fail to erupt. If they push on the other teeth and/or cause pain, they can be removed by a dentist or oral surgeon.

Each tooth has two main divisions, a crown and a root .
The crown has a layer of enamel, an extremely hard outer covering of calcium compounds; dentin, a thick layer of bonelike material; and an inner pulp, which contains the nerves and the blood vessels. Dentin and pulp are also found in the root. Tooth decay, called **dental caries**

The Pharynx

The **pharynx is a region that receives food from the** mouth and air from the nasal cavities. The food passage and air passage cross in the pharynx because the trachea is ventral to the esophagus, a long muscular tube that takes food to the stomach.

The Esophagus

The **esophagus is a muscular tube that passes from the** pharynx through the thoracic cavity and diaphragm into the abdominal cavity where it joins the stomach. The esophagus is ordinarily collapsed, but it opens and receives the bolus when swallowing occurs. A rhythmic contraction called **peristalsis pushes the food along the** digestive tract.

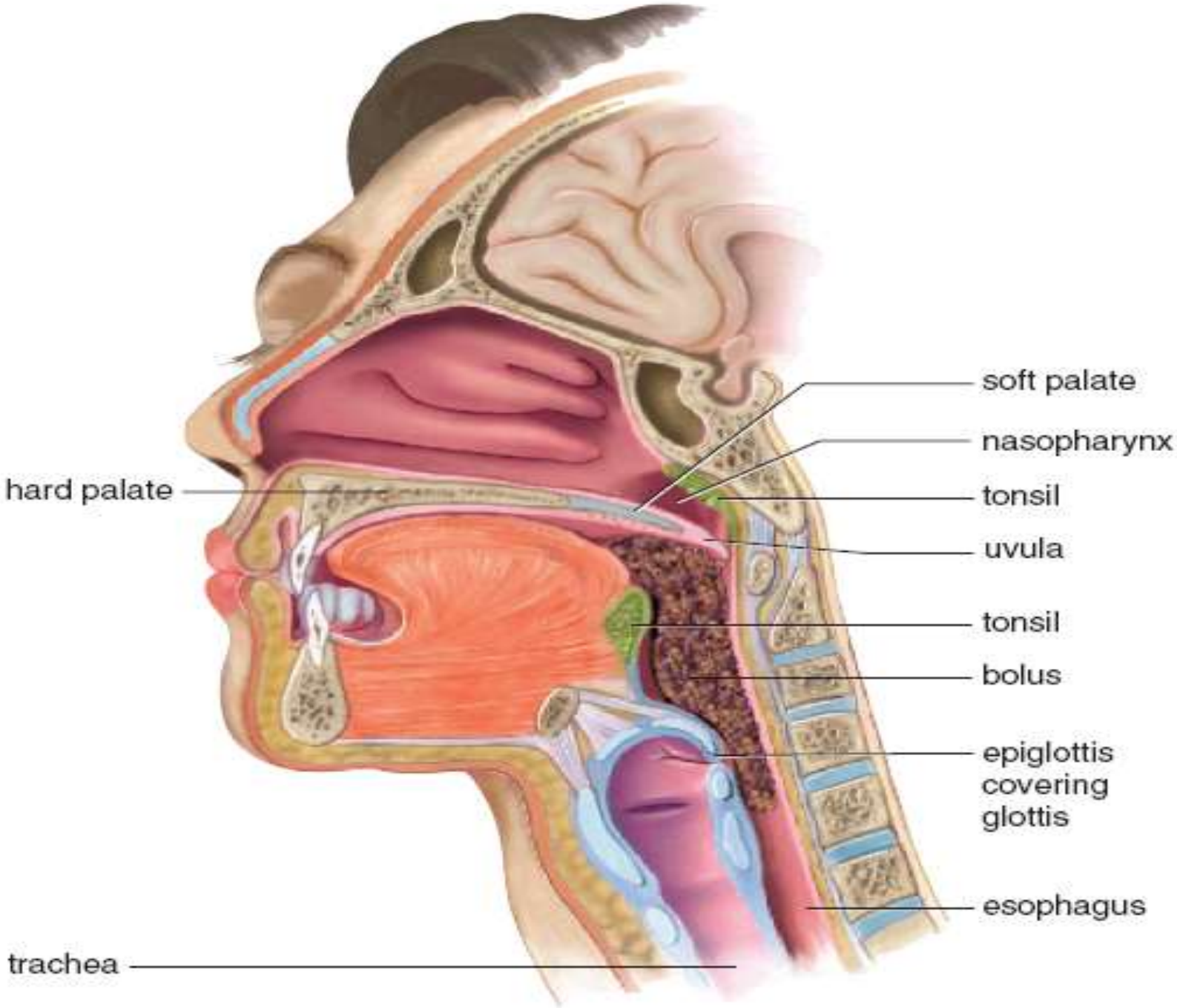
soft palate
nasopharynx
hard palate
tonsil
uvula
tonsil
bolus
epiglottis
covering
glottis
esophagus
trachea

Stomach

The **stomach** is a thick-walled, J-shaped organ that lies on the left side of the body beneath the diaphragm. The stomach is continuous with the esophagus above and the duodenum of the small intestine below. The stomach stores food and aids in digestion. The wall of the stomach has deep folds, which disappear as the stomach fills to an approximate capacity of one liter. Its muscular wall churns, mixing the food with gastric juice. The term *gastric* always refers to the stomach.

The columnar epithelial lining of the stomach (i.e., the mucosa) has millions of gastric pits, which lead into **gastric glands.** The gastric glands produce gastric juice. Gastric juice contains an enzyme called **pepsin,** which digests protein, plus hydrochloric acid (HCl) and mucus. HCl causes the stomach to have a high acidity with a pH of about 2, and this is beneficial because it kills most bacteria present in food. Although HCl does not digest food, it does break down the connective tissue of meat and activates pepsin.

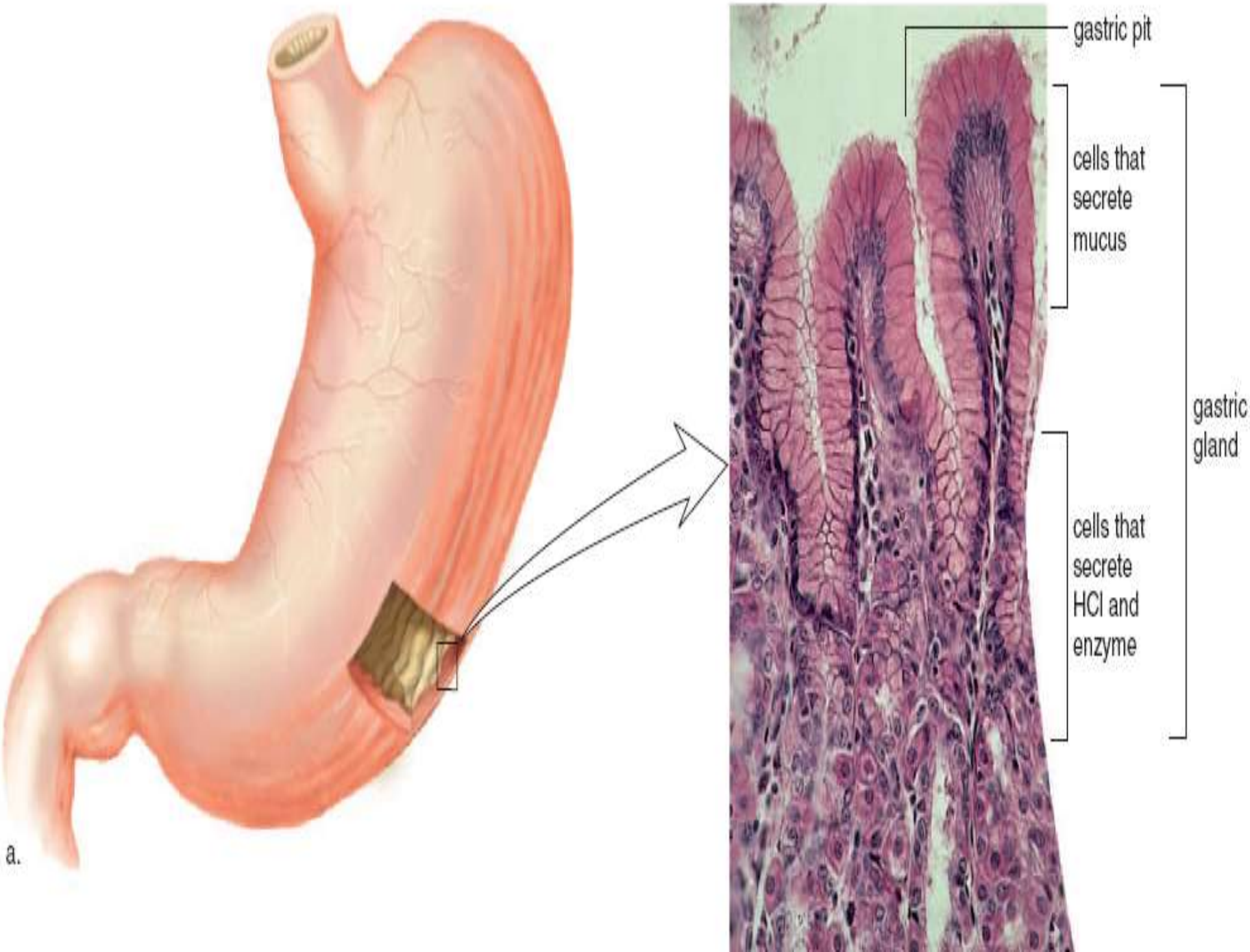
gastric pit
cells that secrete mucus
gastric gland
cells that secrete HCl and enzyme
a.

The Small Intestine

The **small intestine** is named for its small diameter (compared to that of the large intestine), but perhaps it should be called the long intestine. The small intestine averages about 6 meters (18 feet) in length, compared to the large intestine, which is about 1.5 meters (41⁄2 ft) in length. The first 25 cm of the small intestine is called the **duodenum.** Ducts from the liver and pancreas join to form one duct that enters the duodenum .The small intestine receives bile from the liver and pancreatic juice from the pancreas via this duct. **Bile** emulsifies fat—emulsification causes fat droplets to disperse in water. The intestine has a slightly basic pH because pancreatic juice contains sodium bicarbonate ($NaHCO_3$), which neutralizes chyme. The enzymes in pancreatic juice and enzymes produced by the intestinal wall complete the process of food digestion

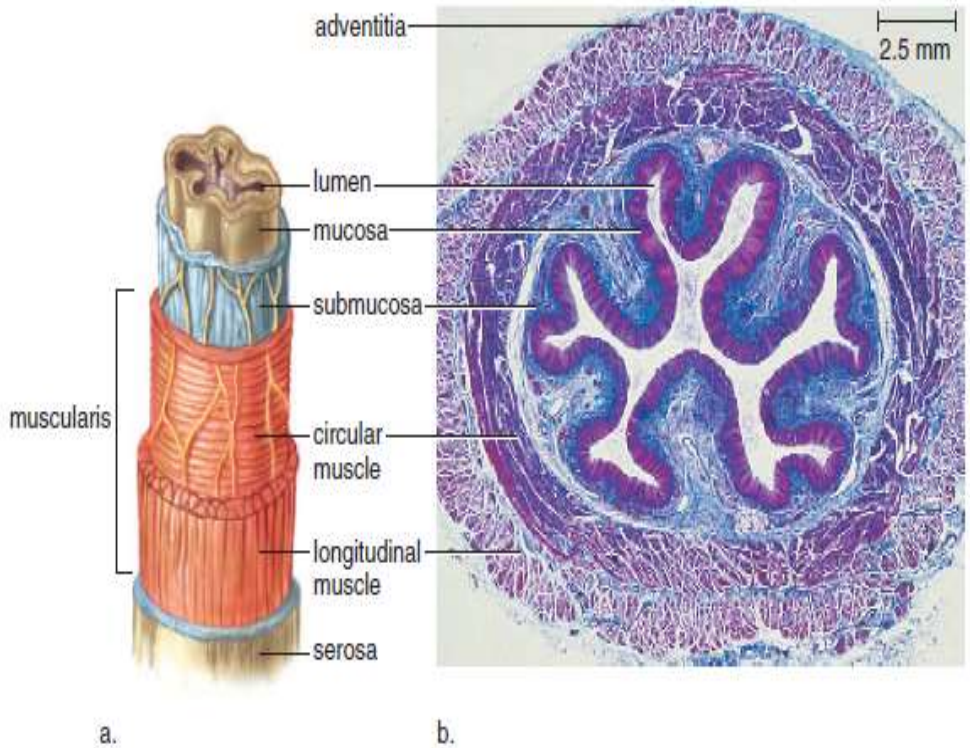

Figure 5.4 Wall of the digestive tract.

a. Several different types of tissues are found in the wall of the digestive tract. Note the placement of circular muscle inside longitudinal muscle.

b. Micrograph of the wall of the esophagus.

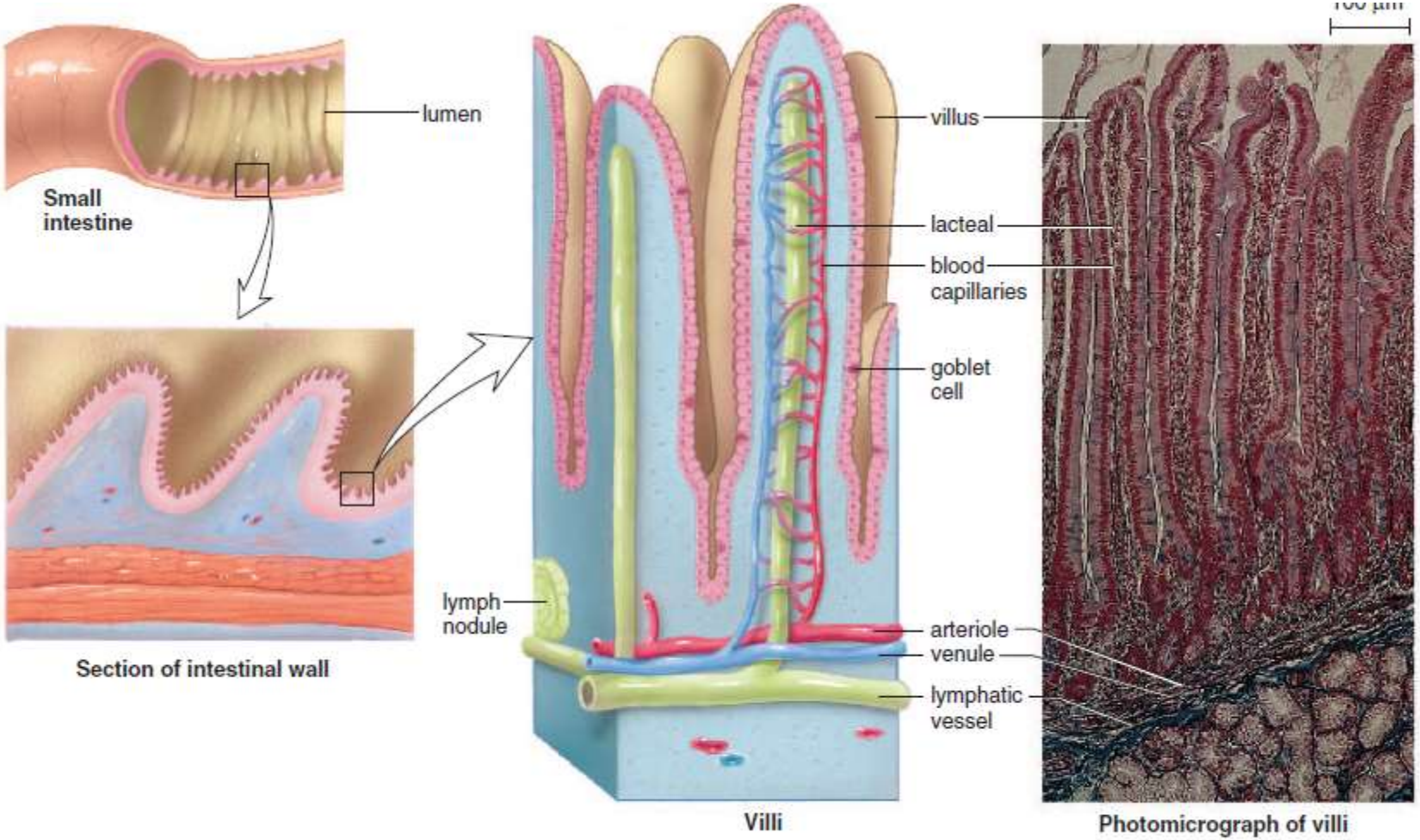

Figure 5.6 Anatomy of the small intestine.
The wall of the small intestine has folds that bear fingerlike projections called villi. The products of digestion are absorbed into the blood capillaries and the lacteals of the villi.

The Large Intestine

The **large intestine,** which includes the cecum, the colon, the rectum, and the anal canal, is larger in diameter than the small intestine (6.5 cm compared to 2.5 cm), but it is shorter in length. The large intestine absorbs water, salts, and some vitamins. It also stores indigestible material until it is eliminated at the anus.The **cecum,** which lies below the junction with the small intestine,is the blind end of the large intestine. The cecum has a small projection called the vermiform

.

The large intestine does not produce digestive enzymes; it does absorb water, salts, and some vitamins.

- **appendix** (*vermiform* means wormlike) .In humans, the appendix also may play a role in fighting infections.
- The **colon** includes the ascending colon, which goes up the right side of the body to the level of the liver; the transverse colon, which crosses the abdominal cavity just below the liver and the stomach; the descending colon, which passes down the left side of the body; and the sigmoid colon, which enters the rectum, the last 20 cm of the large intestine. The rectum opens at the **anus,** where **defecation,** the expulsion of feces, occurs. When feces are forced into the rectum by peristalsis, a defecation reflex

stive system
eviews both
pular diges-
n accessory
le in diges-
y, we recog-

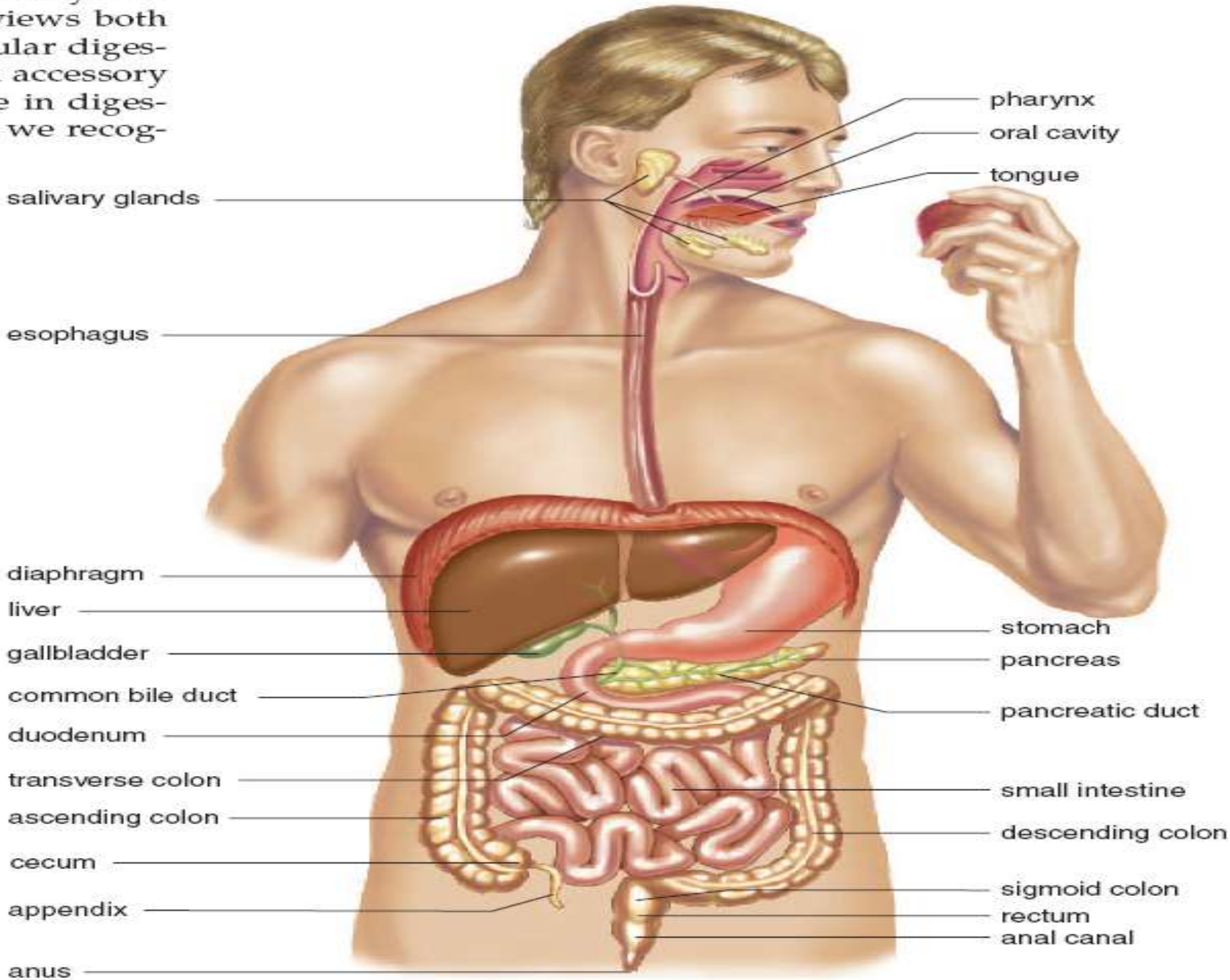

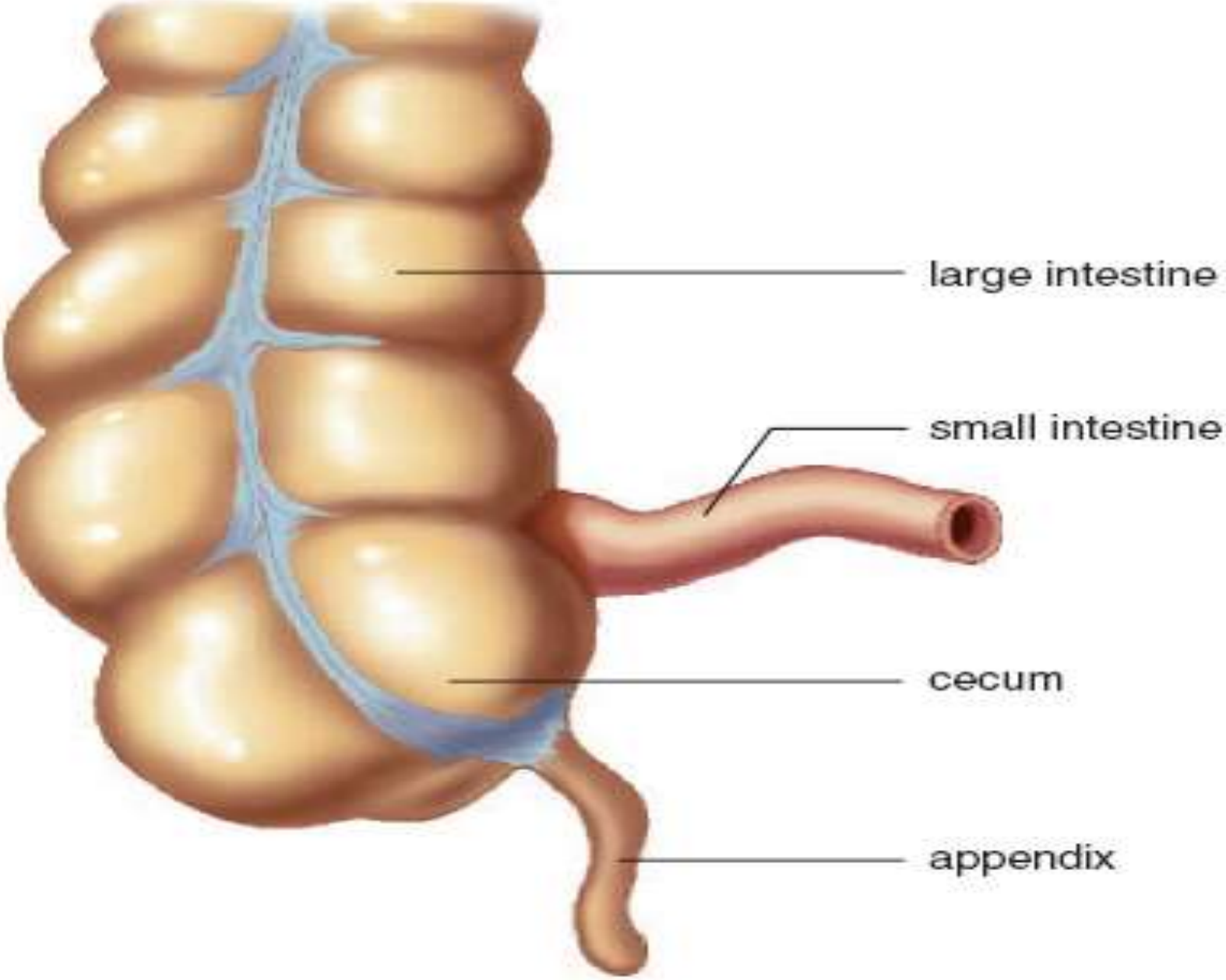
large intestine
small intestine
cecum
appendix

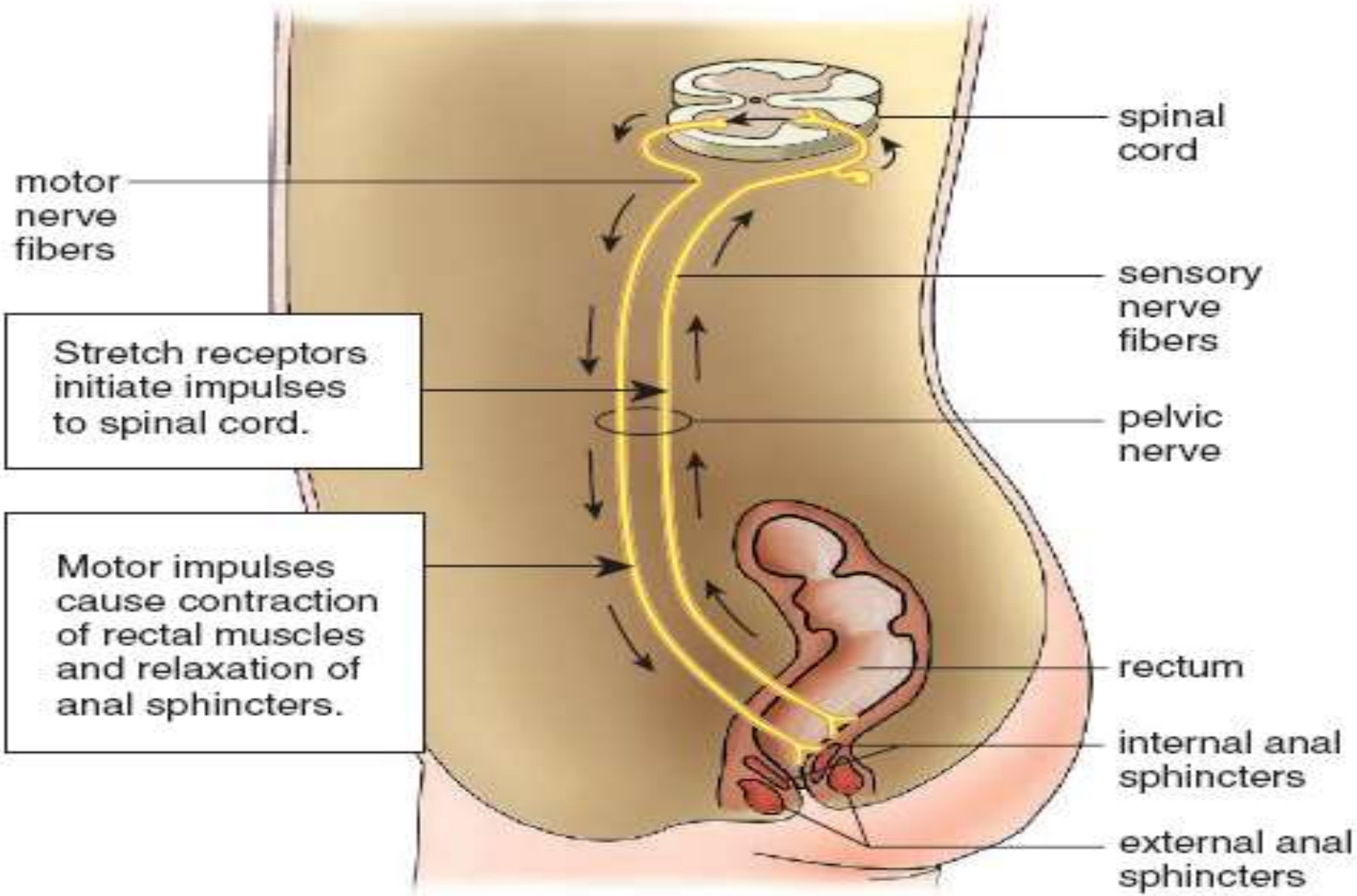
spinal cord
motor nerve fibers
sensory nerve fibers
Stretch receptors initiate impulses to spinal cord.
pelvic nerve
Motor impulses cause contraction of rectal muscles and relaxation of anal sphincters.
rectum
internal anal sphincters
external anal sphincters

Three Accessory Organs

The pancreas, liver, and gallbladder are accessory digestive organs. Figure 5.1 shows how the pancreatic duct from the pancreas and the common bile duct from the liver and gallbladder join before entering the duodenum.

The Pancreas The **pancreas** lies deep in the abdominal cavity, resting on the posterior abdominal wall. It is an elongated and somewhat flattened organ that has both an endocrine and an exocrine function. As an endocrine gland, it secretes insulin and glucagon, hormones that help keep the blood glucose level within normal limits. In this chapter, we are interested in its exocrine function.Most pancreatic cells produce pancreatic juice, which contains sodium bicarbonate ($NaHCO_3$) and digestive enzymes for all types of food. Sodium bicarbonate neutralizes chyme; whereas pepsin acts best in an acid pH of the stomach, pancreatic enzymes require a slightly basic pH. **Pancreatic amylase** digests **starch**, **trypsin** digests **protein,** and **lipase** digests **fat**.

In cystic fibrosis, a thick mucus blocks the pancreatic duct, and the patient must take supplemental pancreatic enzymes by mouth for proper digestion to occur.

The Liver

The **liver,** which is the largest gland in the body, lies mainly in the upper right section of the abdominal cavity, under the diaphragm. The liver has two main lobes, the right lobe and the smaller left lobe, which crosses the midline and lies above the stomach. The liver contains approximately 100,000 lobules that serve as the structural and functional units of the liver .Triads consisting of these three structures are located between the lobules: a bile duct that takes bile away from the liver; a branch of the hepatic artery that brings O2-rich blood to the liver; and a branch of the hepatic portal vein that transports nutrients from the intestines. The central veins of lobules enter a hepatic vein. Trace the path of blood in from the intestines to the liver via the hepatic portal vein and from the liver to the inferior vena cava via the hepatic veins.

The Gallbladder

The **gallbladder** is a pear-shaped, muscular sac attached to the surface of the liver .About 1,000 ml of bile are produced by the liver each day, and any excess is stored in the gallbladder. Water is reabsorbed by the gallbladder so that bile becomes a thick, mucus like material. When needed, bile leaves the gallbladder and proceeds to the duodenum via the common bile duct.

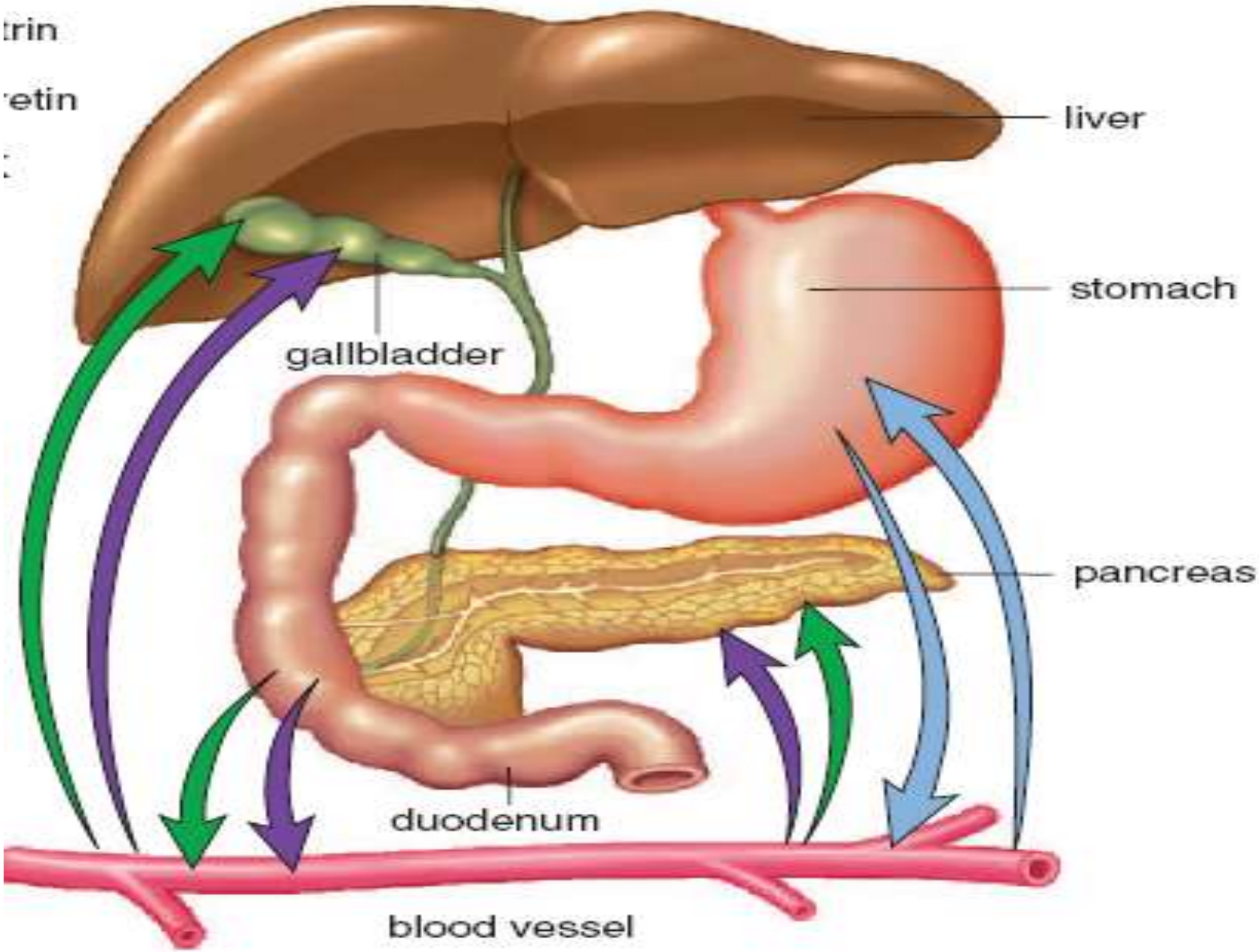
trin
etin
liver
stomach
gallbladder
pancreas
duodenum
blood vessel

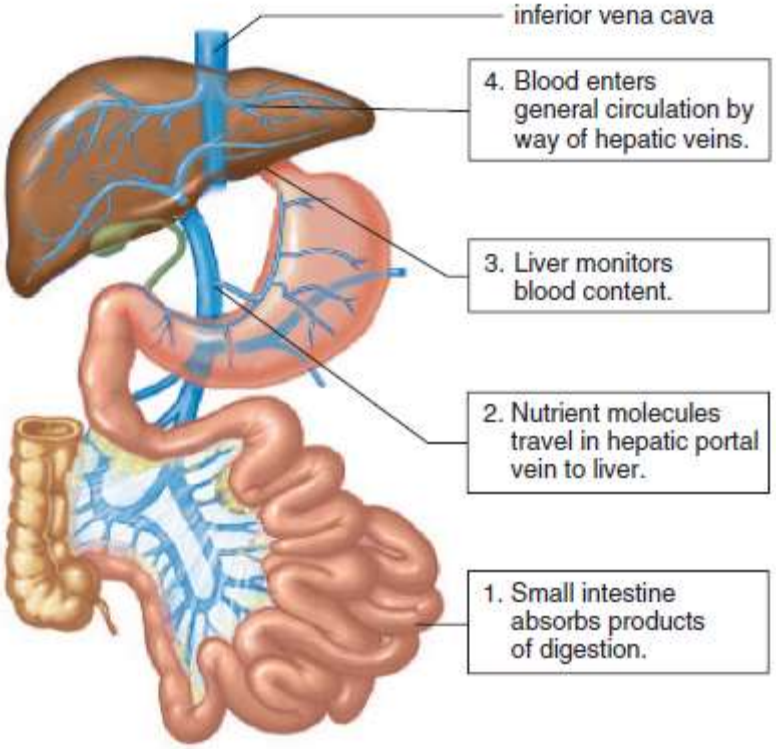

Figure 5.11 Hepatic portal system.
The hepatic portal vein takes the products of digestion from the digestive system to the liver, where they are processed before entering a hepatic vein.

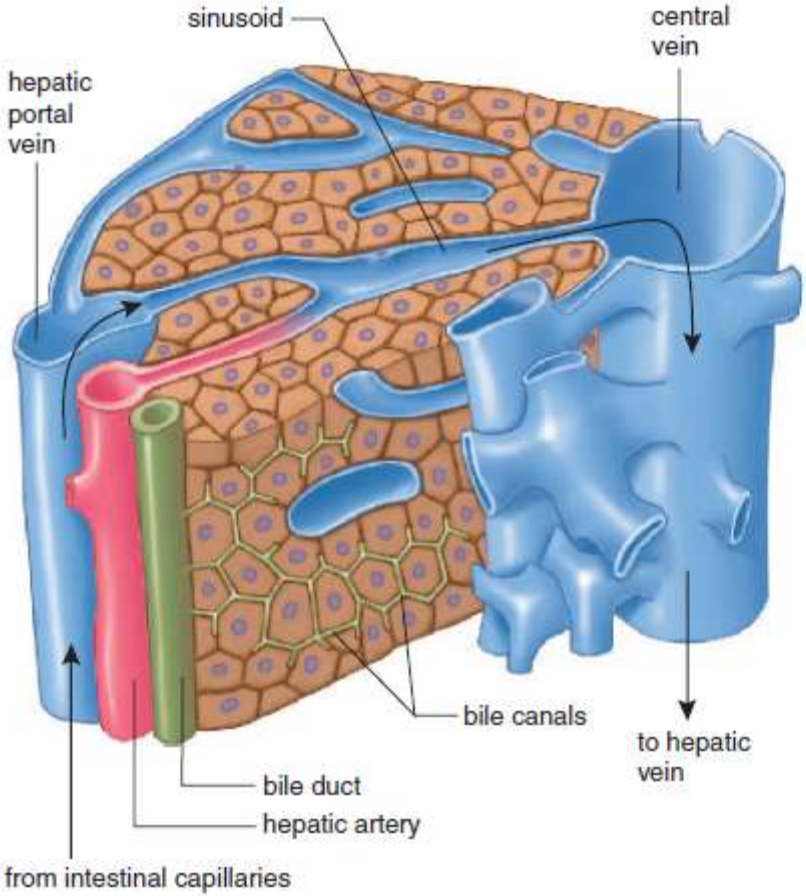

Figure 5.10 Hepatic lobules.
The liver contains over 100,000 lobules. Each lobule contains many cells that perform the various functions of the liver. They remove from and/or add materials to blood and deposit bile in bile ducts.

Table 5.2 Major Digestive Enzymes

Food	Digestion	Enzyme	Optimum pH	Produced By	Site of Action
Starch	Starch + $H_2O \longrightarrow$ maltose	Salivary amylase	Neutral	Salivary glands	Mouth
		Pancreatic amylase	Basic	Pancreas	Small intestine
	Maltose + $H_2O \longrightarrow$ glucose + glucose	Maltase	Basic	Small intestine	Small intestine
Protein	Protein + $H_2O \longrightarrow$ peptides	Pepsin	Acidic	Gastric glands	Stomach
		Trypsin	Basic	Pancreas	Small intestine
	Peptide + $H_2O \longrightarrow$ amino acids	Peptidases	Basic	Small intestine	Small intestine
Nucleic acid	RNA and DNA + $H_2O \longrightarrow$ nucleotides	Nuclease	Basic	Pancreas	Small intestine
	Nucleotide + $H_2O \longrightarrow$ base + sugar + phosphate	Nucleosidases	Basic	Small intestine	Small intestine
Fat	Fat droplet + $H_2O \longrightarrow$ glycerol + fatty acids	Lipase	Basic	Pancreas	Small intestine

5.3 Digestive Enzymes

The digestive enzymes are **hydrolytic enzymes**, which break down substances by the introduction of water at specific bonds. Digestive enzymes, like other enzymes, are proteins with a particular shape that fits their substrate. They also have an optimum pH, which maintains their shape, thereby enabling them to speed up their specific reaction.

The various digestive enzymes present in the digestive juices, mentioned previously, help break down carbohydrates, proteins, nucleic acids, and fats, the major components of food. Starch is a carbohydrate, and its digestion begins in the mouth. Saliva from the salivary glands has a neutral pH and contains **salivary amylase**, the first enzyme to act on starch:

$$\text{starch} + H_2O \xrightarrow{\text{salivary amylase}} \text{maltose}$$

In this equation, salivary amylase is written above the arrow to indicate that it is neither a reactant nor a product in the reaction. It merely speeds the reaction in which its substrate, starch, is digested to many molecules of maltose, a disaccharide. Maltose molecules cannot be absorbed by the intestine; additional digestive action in the small intestine converts maltose to glucose, which can be absorbed.

Protein digestion begins in the stomach. Gastric juice secreted by gastric glands has a very low pH—about 2—because it contains hydrochloric acid (HCl). Pepsinogen, a precursor that is converted to the enzyme **pepsin** when exposed to HCl, is also present in gastric juice. Pepsin acts on protein to produce peptides:

$$\text{protein} + H_2O \xrightarrow{\text{pepsin}} \text{peptides}$$

Peptides vary in length, but they always consist of a number of linked amino acids. Peptides are usually too large to be absorbed by the intestinal lining, but later they are broken down to amino acids in the small intestine.

Starch, proteins, nucleic acids, and fats are all enzymatically broken down in the small intestine. Pancreatic juice, which enters the duodenum, has a basic pH because it contains sodium bicarbonate ($NaHCO_3$). Sodium bicarbonate neutralizes chyme, producing the slightly basic pH that is optimum for pancreatic enzymes. One pancreatic enzyme, **pancreatic amylase**, digests starch:

$$\text{starch} + H_2O \xrightarrow{\text{pancreatic amylase}} \text{maltose}$$

Another pancreatic enzyme, **trypsin**, digests protein:

$$\text{protein} + H_2O \xrightarrow{\text{trypsin}} \text{peptides}$$

Trypsin is secreted as trypsinogen, which is converted to

Lipase, a third pancreatic enzyme, digests fat molecules in the fat droplets after they have been emulsified by bile salts:

$$\text{fat} \xrightarrow{\text{bile salts}} \text{fat droplets}$$

$$\text{fat droplets} + H_2O \xrightarrow{\text{lipase}} \text{glycerol} + \text{fatty acids}$$

The end products of lipase digestion, glycerol and fatty acid molecules, are small enough to cross the cells of the intestinal villi, where absorption takes place. As mentioned previously, glycerol and fatty acids enter the cells of the villi, and within these cells, they are rejoined and packaged as lipoprotein droplets before entering the lacteals (see Fig. 5.6).

Peptidases and **maltase**, enzymes produced by the small intestine, complete the digestion of protein to amino acids and starch to glucose, respectively. Amino acids and glucose are small molecules that cross into the cells of the villi. Peptides, which result from the first step in protein digestion, are digested to amino acids by peptidases:

$$\text{peptides} + H_2O \xrightarrow{\text{peptidases}} \text{amino acids}$$

Maltose, a disaccharide that results from the first step in starch digestion, is digested to glucose by maltase:

$$\text{maltose} + H_2O \xrightarrow{\text{maltase}} \text{glucose} + \text{glucose}$$

Other disaccharides, each of which has its own enzyme, are digested in the small intestine. The absence of any one of these enzymes can cause illness. For example, many people, including as many as 75% of African Americans, cannot digest lactose, the sugar found in milk, because they do not produce lactase, the enzyme that converts lactose to its components, glucose and galactose. Drinking unmixed milk often gives these individuals the symptoms of **lactose intolerance** (diarrhea, gas, cramps), caused by a large quantity of nondigested lactose in the intestine. In most areas, it is possible to purchase milk made lactose-free by the addition of synthetic lactase or *Lactobacillus acidophilus* bacteria, which break down lactose.

Table 5.2 lists some of the major digestive enzymes produced by the digestive tract, salivary glands, or the pancreas. Each type of food is broken down by specific enzymes.

Digestive enzymes present in digestive juices help break down food to the nutrient molecules: glucose, amino acids, fatty acids, and glycerol. The first two are absorbed into the blood capillaries of the villi, and the last two re-form within epithelial cells before entering the lacteals as lipoprotein droplets.

Table 9.1 Major Digestive Enzymes

Enzyme	Produced By	Site of Action	Optimum pH	Digestion
Carbohydrate Digestion				
Salivary amylase	Salivary glands	Mouth	Neutral	Starch + H_2O → maltose
Pancreatic amylase	Pancreas	Small intestine	Basic	Starch + H_2O → maltose
Maltase	Small intestine	Small intestine	Basic	Maltose + H_2O → glucose + glucose
Lactase	Small intestine	Small intestine	Basic	Lactose + H_2O → glucose + galactose
Protein Digestion				
Pepsin	Gastric glands	Stomach	Acidic	Protein + H_2O → peptides
Trypsin	Pancreas	Small intestine	Basic	Protein + H_2O → peptides
Peptidases	Small intestine	Small intestine	Basic	Peptide + H_2O → amino acids
Nucleic Acid Digestion				
Nuclease	Pancreas	Small intestine	Basic	RNA and DNA + H_2O → nucleotides
Nucleosidases	Small intestine	Small intestine	Basic	Nucleotide + H_2O → base + sugar + phosphate
Fat Digestion				
Lipase	Pancreas	Small intestine	Basic	Fat droplet + H_2O → monoglycerides + fatty acids