

## Lecture No . 3

### Integumentary System

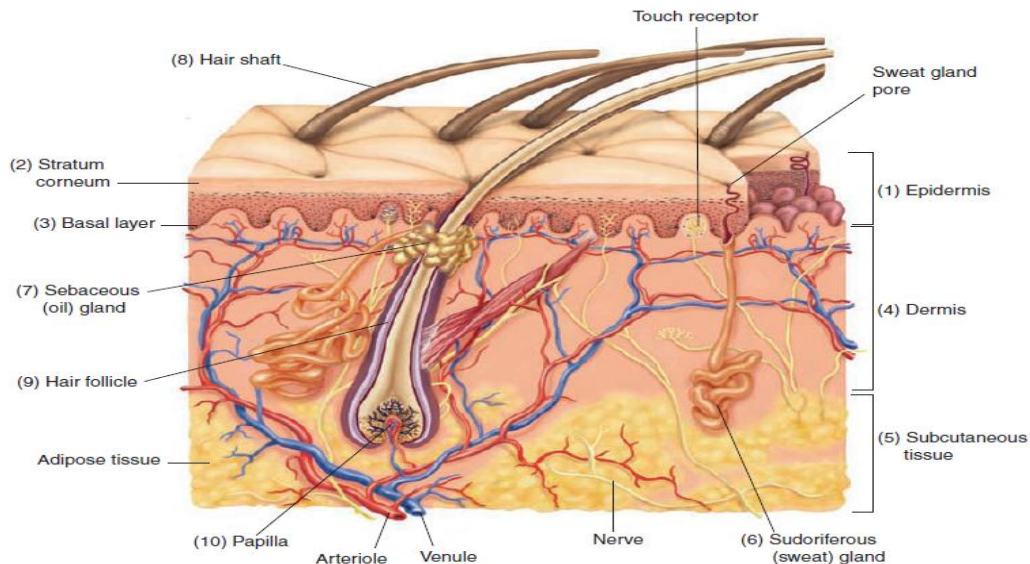


Figure 5-1. Structure of the skin and subcutaneous tissue.

**Integumentary system:** composed of the skin and accessory organs (hair, nails, and glands), the skin also called *integument*, is the largest organ in the body.

#### Skin

The skin protects underlying structures from injury and provides sensory information to the brain. The skin consists of two distinct layers: the **epidermis** and the **dermis**. A **subcutaneous** layer of tissue binds the skin to underlying structures.

**Epidermis:** The outer layer of the skin, and composed of five sublayers called *strata*, such as **stratum corneum** and **basal layer**. In the basal layer, special cells called *melanocytes* produce a black pigment called *melanin*.

melanin has a marked deficiency of pigment in the eyes, hair, and skin and is known as an *albino*.

**Dermis :** The second layer of the skin, the **dermis**, also called *corium*. The **subcutaneous layer**, also called *hypodermis*, binds the dermis to underlying structures. It is composed primarily of loose connective tissue and **adipose** (fat) tissue .

## *Accessory Organs of the Skin*

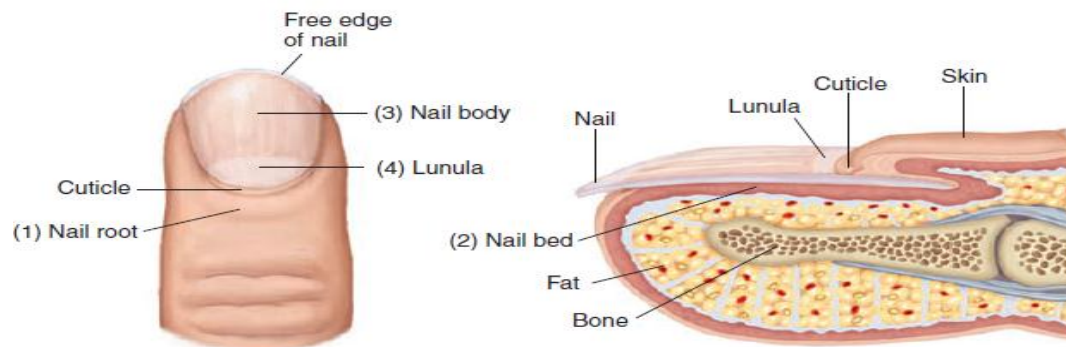
**1- Glands:** Two important glands located in the dermis produce secretions: the **sudoriferous (sweat) glands** produce sweat and the **sebaceous (oil) glands** produce oil or (*sebum*).

### **2- Hair**

Hair is found on nearly all parts of the body except for the lips, nipples, palms of the hands, soles of the feet, and parts of the external genitalia. The hair consist of four part are the **hair shaft** , **root** , **hair follicle** and **papilla** (see above figure).

### **3- Nails**

Nails protect the tips of the fingers and toes from bruises and injuries. Each nail is formed in the **nail root** , **nail bed**, **nail body** and **lunula** .



**Figure 5-2.** Structure of a fingernail.

## *Skin Lesions*

**Lesions** are areas of tissue that have been pathologically altered by injury, wound, or infection. Lesions may affect tissue over an area of a definite size (**localized**) or may be widely spread throughout the body (**systemic**). Evaluation of skin lesions, injuries, or changes to tissue helps establish the diagnosis of skin disorders. Lesions are described as primary or secondary. **Primary skin lesions** are the initial reaction to **pathologically** altered tissue and may be flat or elevated. **Secondary skin lesions** are changes that take place in the primary lesion due to infection, scratching, trauma, or various stages of a disease. Lesions are also described by their appearance, color, location, and size as measured in centimeters. Some of the major primary and secondary skin lesions are showing below.

## PRIMARY LESIONS

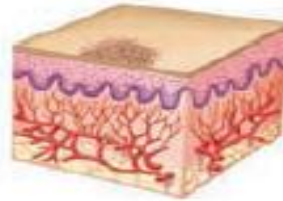### FLAT LESIONS

*Flat, discolored, circumscribed lesions of any size*

#### Macule

Flat, pigmented, circumscribed area less than 1 cm in diameter.

**Examples:** freckle, flat mole, or rash that occurs in rubella.



### ELEVATED LESIONS

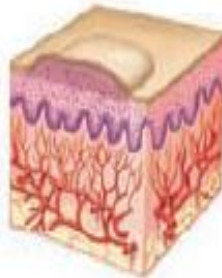
*Solid*

*Fluid-filled*

#### Papule

Solid, elevated lesion less than 1 cm in diameter that may be the same color as the skin or pigmented.

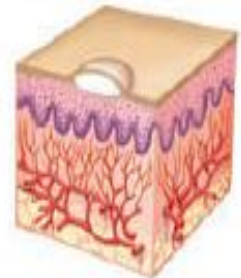
**Examples:** nevus, wart, pimple, ringworm, psoriasis, eczema.



#### Vesicle

Elevated, circumscribed, fluid-filled lesion less than 0.5 cm in diameter.

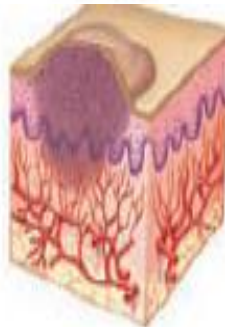**Examples:** poison ivy, shingles,



#### Nodule

Palpable, circumscribed lesion; larger and deeper than a papule (0.6 to 2 cm in diameter); extends into the dermal area.

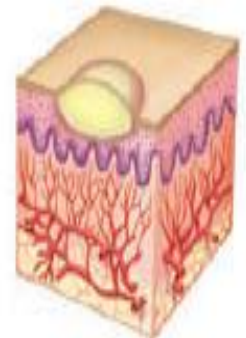
**Examples:** intradermal nevus, benign or malignant tumor.



#### Pustule

Small, raised, circumscribed lesion that contains pus; usually less than 1 cm in diameter.

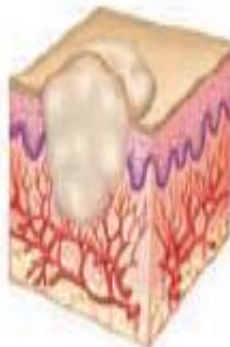**Examples:** acne, furuncle, pustular psoriasis, scabies.



#### Tumor

Solid, elevated lesion larger than 2 cm in diameter that extends into the dermal and subcutaneous layers.

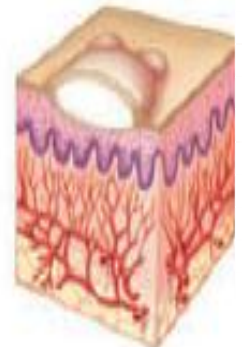**Examples:** lipoma, steatoma, dermatofibroma, hemangioma.



#### Bulla

A vesicle or blister larger than 1 cm in diameter.

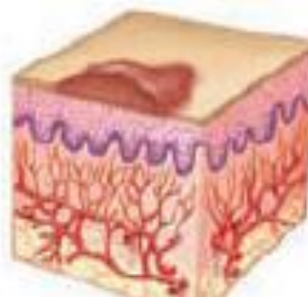
**Examples:** second degree burns, severe poison oak, poison



#### Wheal

Elevated, firm, rounded lesion with localized skin edema (swelling) that varies in size, shape, and color; paler in the center than its surrounding edges; accompanied by itching.

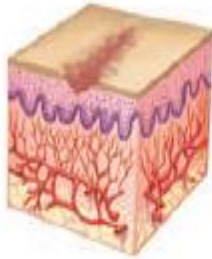
**Examples:** hives, insect bites,



## SECONDARY LESIONS

### DEPRESSED LESIONS

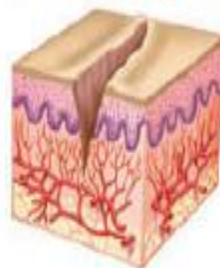*Depressed lesions caused by loss of skin surface*



#### Excoriations

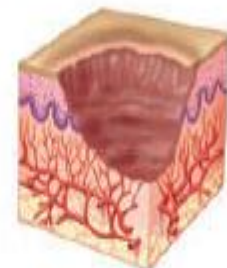Linear scratch marks or traumatized abrasions of the epidermis.

**Examples:** scratches, abrasions, chemical or thermal burns.



#### Fissure

Small slit or crack like sore that extends into the dermal layer; could be caused by continuous inflammation and drying.



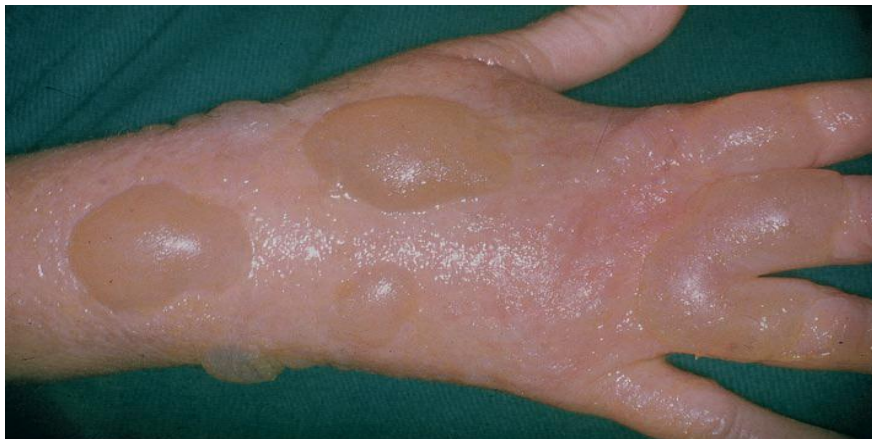#### Ulcer

An open sore or lesion that extends to the dermis and usually heals with scarring.

**Examples:** pressure sore, basal cell carcinoma.

## Burns

Burns are tissue injuries caused by contact with thermal, chemical, electrical, or radioactive agents. Although burns generally occur on the skin, they can also affect the respiratory and digestive tract linings. Burns that have a local effect are not as serious as those that have a systemic effect. Burns are usually classified as first-, second-, or third-degree burns.



## Oncology

**Neoplasms** are abnormal growths of new tissue that are classified as benign or malignant. **Benign neoplasms** are noncancerous growths composed of the same type of cells as the tissue in which they are growing. **Malignant neoplasms** are composed of cells that are invasive and spread to remote regions of the body. These cells show altered function, altered appearance, and uncontrolled growth.

**Malignant melanoma** is a neoplasm composed of abnormal melanocytes that commonly begin in a darkly pigmented mole. Although malignant melanoma is relatively rare, the incidence is rising more rapidly than any other malignancy.

### Pharmacology

Various medications are available to treat skin disorders. Because of their superficial nature and location, many skin disorders respond well to topical drug therapy. Such mild, localized skin disorders as contact dermatitis, acne, poison ivy, and diaper rash can be effectively treated with topical agents available as over-the-counter products.

## Drugs Used to Treat Skin Disorders

Classification	Therapeutic Action	Generic and Trade Names
antifungals	<p>Alter the cell wall of fungi or disrupt enzyme activity, resulting in cell death</p> <p><i>Antifungals are used to treat ringworm (tinea corporis), athlete's foot (tinea pedis), and fungal infection of the nail (onychomycosis). When topical antifungals are not effective, oral or intravenous antifungal drugs may be necessary.</i></p>	<p><b>nystatin</b> NĪS-tă-tĭn Mycostatin, Nyston</p> <p><b>itraconazole</b> ĭt-ră-KÖN-ă-zōl Sporanox</p>
antihistamines	<p>Inhibit allergic reactions of inflammation, redness, and itching caused by the release of histamine</p> <p><i>In a case of severe itching, antihistamines may be given orally. As a group, these drugs are also known as antipruritics (pruritus means itching).</i></p>	<p><b>diphenhydramine</b> dĭ-fĕn-HĪ-dră-mĕn Benadryl</p> <p><b>loratadine</b> lor-ĂH-tă-dĕn Claritin</p>
antiseptics	<p>Topically applied agents that inhibit growth of bacteria, thus preventing infections in cuts, scratches, and surgical incisions</p>	<p><b>ethyl or isopropyl alcohol</b> ĔTH-ĭl ĩ-sō-PRŌ-pĭl</p> <p><b>hydrogen peroxide</b> HĪ-drŏ-jĕn pĕ-RŌK-sĭd</p>

parasiticides

Kill insect parasites, such as mites and lice  
*Parasiticides are used to treat scabies (mites) and pediculosis (lice). The drug is applied as a cream or lotion to the body and as a shampoo to treat the scalp.*

**lindane**  
 LĪN-dān  
 Kwell, Thion  
**permethrin**  
 pĕr-MĒTH-rĭn  
 Nix

### Abbreviations

*This section introduces integumentary-related abbreviations and their meanings.*

Abbreviation	Meaning	Abbreviation	Meaning
Bx, bx	biopsy	ID	intra-dermal
BCC	basal cell carcinoma	I&D	incision and drainage
CA	cancer; chronological age; cardiac arrest	IMP	impression (synonymous with diagnosis)
cm	centimeter	IV	intravenous
decub	decubitus (ulcer)	subcu, Sub-Q, subQ	subcutaneous (injection)
derm	dermatology	ung	ointment
FS	frozen section	XP, XDP	xeroderma pigmentosum