

## Lecture No . 2

# Body structure

### *Levels of Organization*

The body is made up of several levels of structure and function. Each of these levels builds on the previous level, and contributes to the structure and function of the entire organism.

The levels of organization from least to most complex are:

**Cell** :- The study of the body at the cellular level is called **cytology**. The cell is the structural and functional unit of life.

**Tissue** :- Groups of cells that perform a specialized activity are called tissues. The study of tissues is called **histology**. More than 200 cell types compose four major tissues of the body:

- 1- Epithelial tissue covers surfaces of organs, lines cavities and canals, forms tubes and ducts, provides the secreting portions of glands, and makes up the epidermis of the skin.
- 2- Connective tissue supports and connects other tissues and organs. It is made up of diverse cell types, including fibroblasts, fat cells, and blood.
- 3- Muscle tissue provides the contractile tissue of the body, which is responsible for movement.
- 4- Nervous tissue transmits electrical impulses as it relays information throughout the entire body.

**Organ**:- Organs are body structures that perform specialized functions. They are composed of at least two or more tissue types. For example, the stomach is made up of connective tissue, muscle tissue, epithelial tissue, and nervous tissue.

**System** :- A body system is composed of varying numbers of organs and accessory structures that have similar or related functions. For example, organs of the gastrointestinal system include the esophagus, stomach, small intestine, and bowel. Some of its accessory structures include the liver, gallbladder, and pancreas.

**Organism**:- The highest level of organization is the organism. An organism is a complete living entity capable of independent existence. All complex organisms, including humans, are made up of several body systems that work together to sustain life.

### *Anatomical Position:*

The **anatomical position** is a body posture used to locate anatomical parts in relation to each other. In this position, the body is erect and the eyes are looking forward. The upper limbs hang to the sides, with the

palms facing forward. The lower limbs are parallel, with toes pointing straight ahead.

### ***Planes of the Body***

To identify the different sections of the body, anatomists use an imaginary flat surface called a **plane**. The most commonly used planes are **midsagittal** (median), **coronal** (frontal), and **transverse** (horizontal). The section is named for the plane along which it is cut. Thus, a cut along a transverse plane produces a transverse, or horizontal, section.

<b>Table 4-1 Planes of the Body</b>	
<i>This table lists planes of the body and their anatomical divisions.</i>	
<b>Plane</b>	<b>Anatomical Division</b>
Midsagittal (median)	Right and left halves
Coronal (frontal)	Anterior (ventral) and posterior (dorsal) aspects
Transverse (horizontal)	Superior (upper) and inferior (lower) aspects

### ***Body Cavities***

Medical professionals locate structures or abnormalities by referring to the body cavity in which they are found. The body has two major cavities:

- 1- dorsal (posterior), including the cranial and spinal cavities
- 2- ventral (anterior), including the thoracic and abdominopelvic cavities.

### ***Abdominopelvic Divisions:***

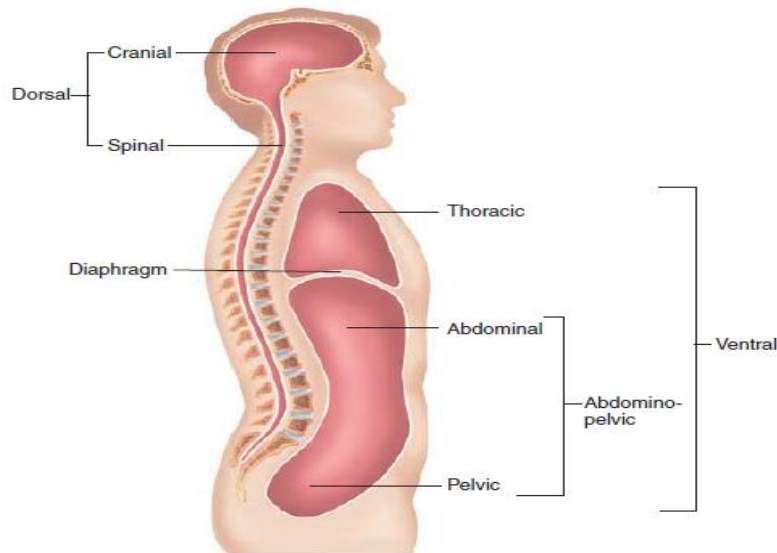
The abdominopelvic area of the body lies beneath the **diaphragm**. It holds the organs of digestion (abdominal area) and the organs of reproduction and excretion (pelvic area). Two anatomical methods are used to divide this area of the body for medical purposes:

- quadrants
- regions.

Table 4-2 **Body Cavities**

*This table lists the body cavities and some of the major organs found within them. The thoracic cavity is separated from the abdominopelvic cavity by a muscular wall called the diaphragm.*

Cavity	Major Organ(s) in the Cavity
<b>Dorsal</b>	
Cranial	Brain
Spinal	Spinal cord
<b>Ventral</b>	
Thoracic	Heart, lungs, and associated structures
Abdominopelvic	Digestive, excretory, and reproductive organs and structures



**Figure 4-3.** Body cavities.

**Quadrants:** are four divisions of the lower torso used to show topographical location. They provide a means of locating specific sites for descriptive and diagnostic purposes. The divisions of quadrants are used in clinical examinations and medical reports. Pain, lesions, abrasions, punctures, and burns are commonly described as located in a specific quadrant.

**Regions:**

Whereas the quadrants of the body are used primarily to identify topographical sites, the **abdominopelvic regions** are used mainly to identify the location of underlying body structures and visceral organs. For example, the stomach is located in the left hypochondriac and epigastric region; the appendix is located in the hypogastric region.

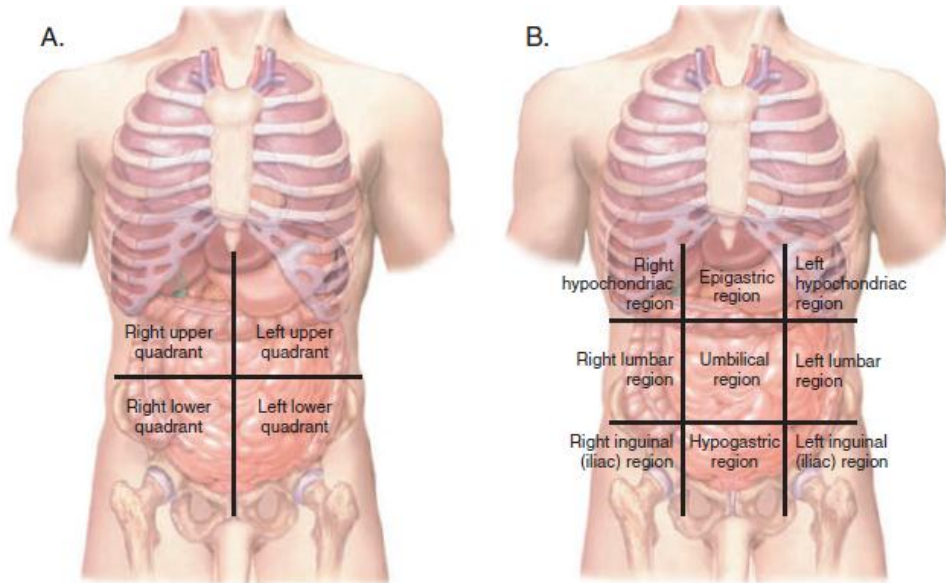


Figure 4-4. Quadrants and regions. (A) Four quadrants of the abdomen. (B) Nine regions of the abdomen.

Table 4-3 Body Quadrants		
<i>This table lists the quadrants of the body, their corresponding abbreviations, and their major structures.</i>		
Quadrant	Abbreviation	Major Structures
Right upper	RUQ	Right lobe of liver, gallbladder, part of pancreas, part of small and large intestines
Left upper	LUQ	Left lobe of liver, stomach, spleen, part of pancreas, part of small and large intestines
Right lower	RLQ	Part of small and large intestines, appendix, right ovary, right fallopian tube, right ureter
Left lower	LLQ	Part of small and large intestines, left ovary, left fallopian tube, left ureter

Table 4-4 Abdominopelvic Regions	
<i>This table lists the names of the abdominopelvic regions and their location.</i>	
Region	Location
Left hypochondriac	Upper left region beneath the ribs
Epigastric	Region above the stomach
Right hypochondriac	Upper right region beneath the ribs
Left lumbar	Left middle lateral region
Umbilical	Region of the navel
Right lumbar	Right middle lateral region
Left inguinal (iliac)	Left lower lateral region
Hypogastric	Lower middle region beneath the navel
Right inguinal (iliac)	Right lower lateral region

**Spine:**

The spine is divided into sections corresponding to the vertebrae located in the spinal column. These divisions are:

- cervical (neck)
- thoracic (chest)
- lumbar (loin)
- sacral (lower back)
- coccyx (tailbone)

**Directional Terms:**

Directional terms are used to show the position of a structure in relation to another structure. For example, the kidneys are superior to the urinary bladder. The directional phrase *superior to* denotes *above*. This example indicates that the kidneys are located above the urinary bladder.

Table 4-5 Directional Terms—cont'd	
Term	Definition
Medial	Pertaining to the midline of the body or structure
Lateral	Pertaining to a side
Superior (cephalad)	Toward the head or upper portion of a structure
Inferior (caudal)	Away from the head, or toward the tail or lower part of a structure
Proximal	Nearer to the center (trunk of the body) or to the point of attachment to the body
Distal	Further from the center (trunk of the body) or from the point of attachment to the body
Anterior (ventral)	Front of the body
Posterior (dorsal)	Back of the body
Parietal	Pertaining to the outer wall of the body cavity
Visceral	Pertaining to the viscera, or internal organs, especially the abdominal organs
Prone	Lying on the abdomen, face down
Supine	Lying horizontally on the back, face up
Inversion	Turning inward or inside out
Eversion	Turning outward
Palmar	Pertaining to the palm of the hand
Plantar	Pertaining to the sole of the foot
Superficial	Toward the surface of the body (external)
Deep	Away from the surface of the body (internal)

## Abbreviations

*This section introduces body structure abbreviations and their meanings.*

Abbreviation	Meaning	Abbreviation	Meaning
ant	anterior	MRI	magnetic resonance imaging
AP	anteroposterior	PET	positron emission tomography
Bx, bx	biopsy	post	posterior
CBC	complete blood count	RF	rheumatoid factor; radio frequency
CT	computed tomography	RLQ	right lower quadrant
DNA	deoxyribonucleic acid	RUQ	right upper quadrant
DSA	digital subtraction angiography	sono	sonogram
Dx	diagnosis	SPECT	single photon emission computed tomography
FS	frozen section	Sx	symptom
I&D	incision and drainage	Tx	treatment
LAT, lat	lateral	UA	urinalysis
LLQ	left lower quadrant	U&L, U/L	upper and lower
LUQ	left upper quadrant	US	ultrasound ultrasonography