

Parasitology

Organisms relationships

1. **Symbiosis:** (living together) the relationship between two individuals depend one to other and it can't live without the other, Ex. Termid and Hyper flagellate.

2. **Commensalism :** (eating at the same table) the relationship between two individuals the first obtains the food or habitat or both from the another without causes any damage in it Ex. *Entamoeba coli* in human.

3. **Parasitism:** (eating at the table of others) the relationship between two individual the first (parasite)obtain the food or habitat or both.

from the another (host) and must be causes damage in it , Ex. *Entamoeba histolytica* in human.

Parasitology

The science which studing the relationship between different kinds of organism .The smollest is a parasite all most invertbrate and the host which abiger all most vertbrate .

This science consist of three branches:

1. **Medical protozology** which studying the unicellular parasite Ex. *Entamoeba histolytica* .

2. **Medical Helmenthology** which studying the parasitic flat and round worms Ex. *Fasciola hepatica* , *Ascaris lumbricodis*.

3. **Medical Entomology** which studying the medical Erythro podes Ex. Mosquit .

The parasites can be divided into two groups:

1. **Ectoparasite** consist of the parasitic groups which infested on host skin or external parts of the host body Ex. mosquito , pediculous , ticks which causes infestation
2. **Endoparasite** consist of the parasitic groups infected internal parts of the body Ex. *Giardia lamblia* , Plasmodium spp. , Leishmania spp. which causes infection.

Types of parasitism

1: **Facultative parasite**: the parasite which can living in his life cycle as a parasitic or as free living Ex. *Strongyloides stracularis*, *Crysoma buziana*.

2: **Obligatory parasite**: this group must be living as a parasitic in all his life cycle or part of it and we can divided it to:

A . Temporary obligatory parasite this parasites are visit the host between time to time and obtains food or take Blood meal of it Ex. Mosquito.

B : Sporadic obligatory parasite this parasite living in part of his life cycle as a parasitic on the external parts of the body host and in second part of his life cycle free living Ex. ticks mites.

C : Permanent obligatory parasite : this parasitic group must be living all his life cycle as a parasitic on or in the hosts, Ex. Pediculous, *Entamoeba histolytica*. Plasmodium spp.

Zoonosis diseases consist of the veterinary diseases which transport between vertebrate animals only .Ex. Theileria.

Zoonotic diseases consist of common diseases which infected human and animals Ex. Hydated cyst

Type of hosts

1 : (final ,definitive , primay) the host infected with adult stage or sexual phase of parasite which produce eggs or larvae Ex. human infected with *Ascaris*, *Ancylostoma*.

2 : Intermediate or secondary host : the host infected with larval stage or asexual phase of parasite and **must be** important or essential to complete the life cycle of parasite, Ex. Herbivorous animals infected with hydated cyst.

3 : Accidental host :the host ordinary infected with larval stage of parasite but it is not essential to complete it's life cycle, Ex. Human infected with Hydated cyst or *Fasciola hepatica*.

4 : Recervior host: the host infected with larval stage but without symptoms and it important as a source of infection Ex. dogs infected with *Leishmania* .

5 : Vector host: the invertbrate host which transport the infected stage of parasite from the host to another and it can be divided to biological vector like mosquito or mechanical vector house fly .

Major categories of classification

Kingdom , Phylum , Class , Order , Family , Genouse , Species .

1 – Protozoa : Unicellular parasite contains one or more nuclei in troph & four or more cystic stage motile by means of locomotion or nonmotile,

production by binary fission or chizogony can produced by sexual process. The protozoa classified to four classes depend on locomotion organulla.

A - Sarcodyna (Amoeba)is related to two stages :Trophozoit & cyst through it`s life cycle.

The troph can live inside the host and multiplies with in it. In the external environment the troph will transform in to cyst.The mode of locomotion occurs due to a presence of pseudo podia .The mode of reproductive is by binary fission .The main parasite with clinically important as following :

Entamoeba hystolytia , Entamoeba coli , Entamoeba gingivalis

Neagleria fowleri

B- .Mastigophora (Flagellata)

1 - Intestinal flagellate :

The movement occurs due to presence of flagella the No. of flagella differs from one to other .The mode of production binary fission. In life cycle of it is troph and cyst.

The main spp. : - *Giardia lamblia*

2 - Blood flagellate(Haemo flagellata)

Leishmania spp. Trypanasoma spp

3- Atrial flagellate :

Trichomonas vaginalis

C - Ciliata

Only one species is medically important. [*Balantidium coli*], in this class movement occurred due to presence of cilia, the mode of production is binary fission or conjugation in the life cycle, there is a troph & cyst

D - Sporozoa

The mode of production is by schizogony.

Non motile, Need more than one host, Sexual & asexual cycle can be occurs due to the live cycle The main spp. Are:

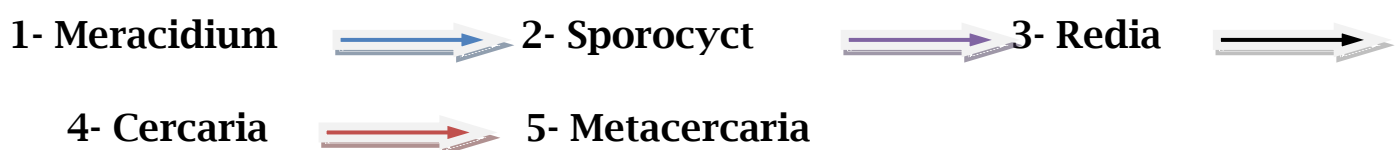-*Plasmodium* spp. (malaria) -*Toxoplasma gondii* *Sarcocystis hominis*

2-Worms

The worms /metazoa are multi cellular parasite. Large in size and contain many stages in their life cycle . Ther are three classes of helminthes:

A- Termatoda

The worm of trematoda is leaf like structure contains 2 suckers ,oral are ventral suckers reproductive sys. present in a same w.eexcept *Schistosoma* spp.. Life cycle of them are: eggs ,multiple larvae and adult .The larval stage are :



Each larval stage may need host for development, in trematoda many host should be present for complete his life cycle .

The main spp,

-Faciola hepatica - *Clonorchis sinensis* - *Fasciolapsis buski*

-Hetcrophyes heterophys -*Paragonimus westermani* -*Schistosoma spp.*

B - Cestoda (tapeworm)

Cestoda : contains head ,neck and segments , the head is called scolex and the segments called proglottides .There are 3 types of proglottides : immature ,mature .gravid.

Male and female reproductive sys. are present in same worm.So it called Hermaphrodite. There are 3 stages in their life cycle :egg, larva and adult ,same of them need more than host, main species :

Taenia solium *Taenia saginata* *Dipylidium caninum*

Hymenolepis nana *Echinococcus spp.* *Diphyllobothrium latum*

C - Nematoda

The w.of nematoda differ from others two classes in the sex separated in two w`s. ♀&♂. So conception occurs after meeting. There are: eggs ,larvae & adult .The w. May needs two or more host according to it's life cycle. . Some spp. don't put eggs after meeting instead larva is motled directly.

The main spp. :

-Enterobius vermicularis -*Ascaris lumbricoides* -*Ancylostoma duodenale*

-Trichuris tricura -*Trichirella spiralis* *Wecheraria bancrofti*

Dracanculous medinansis

Arthro poda

It consist some groups of insect which infested on human and animal and it consider as a vectors host to another parasite as a vector to plasmodium .

The important medical insects are : **mosquito** , **pediculous** , **Glossinia spp.** , **Tritomid spp.** , **Phlebotomas spp.** , **Zenopselos spp.**, **Domestica spp.** . And some Erythropodes like Ticks, Mites & Arachinyda.

PROTOZOA

Protozoan parasites consist of a single "cell-like unit" which is morphologically and functionally complete and can perform all functions of life. They are made up of a mass of protoplasm differentiated into cytoplasm and nucleoplasm.

The cytoplasm consists of an outer layer of hyaline ectoplasm and an inner voluminous granular endoplasm.

The ectoplasm functions in protection, locomotion, and ingestion of food, excretion, and respiration. In the cytoplasm there are different vacuoles responsible for storage of food, digestion and excretion of waste products.

The nucleus also functions in reproduction and maintaining life.

The protozoal parasite possesses the property of being transformed from an active (trophozoite) to an inactive stage, losing its power of motility and enclosing itself within a tough wall. The protoplasmic body thus formed is known as a cyst. At this stage the parasite loses its power to grow and multiply.

The cyst is the resistant stage of the parasite and is also infective to the human host.

Reproduction

– the methods of reproduction or multiplication among the parasitic protozoa are of the following types:

1. Asexual multiplication:

(a) Simple binary fission – in this process, after division of all the structures, the individual parasite divides either longitudinally or transversely into two more or less equal parts.

(b) Multiple fission or schizogony – in this process more than two individuals are produced, e.g. asexual reproduction in Plasmodia.

2. Sexual reproduction:

(a) Conjugation – in this process, a temporary union of two individuals occurs during which time interchange of nuclear material takes place. Later on, the two individuals separate.

(b) Syngamy – in this process, sexually differentiated cells, called gametes, unite permanently and a complete fusion of the nuclear material takes place. The resulting product is then known as a zygote.

Protozoa are divided into four types classified based on their organs of locomotion. These classifications are: Sarcodina, ciliates, flagellates, and sporozoans.

INTRODUCTION

Protozoa (singular, protozoan), from the Greek 'protos' and 'zoon' meaning "first animal", are members of eukaryotic protists. They may be distinguished from other eukaryotic protists by their ability to move at some stage of their life cycle and by their lack of cell wall .

Transmission

In most parasitic protozoa, the developmental stages are often transmitted from one host to another within a cyst. The reproduction process is also related to the formation of the cyst. Asexual reproduction of some ciliates and flagellates is associated with cyst formation, and sexual reproduction of Sporozoa invariably results in a cyst. Pathogenic protozoa can spread from one infected person to another by:

- 1- Faecal – oral transmission of contaminated foods and water.
- 2- Insect bit inoculums or rubbing infected insect faeces on the site of bite.
- 3- Sexual intercourse .

AMOEBIASIS

Amoebas primitive unicellular microorganisms with a relatively simple life cycle which can be divided into two stages:

- 1- **Trophozoite** – actively motile feeding stage.
- 2- **Cyst** – quiescent, resistant, infective stage.

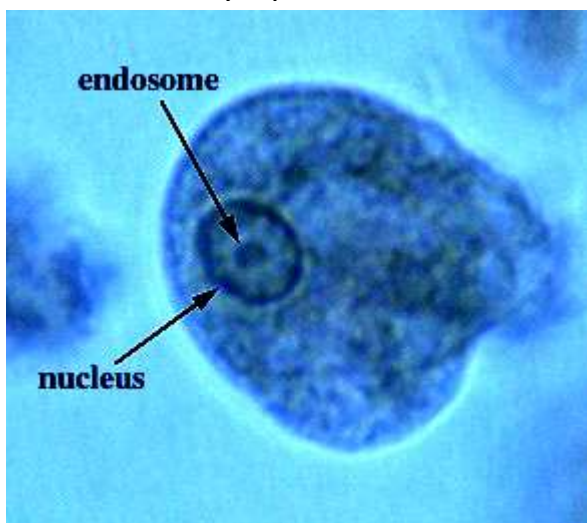
Their reproduction is through binary fission, e.g. splitting of the trophozoite or through the development of numerous trophozoites within the mature multinucleated cyst. Motility is accomplished by extension of pseudopodia .

Entamoeba histolytica

Morphological features


(a) Trophozoites

Viable trophozoites vary in size from about 10-60µm in diameter. Motility is rapid, progressive, and unidirectional, through pseudopods. The nucleus is characterized by evenly arranged chromatin on the nuclear membrane and the presence of a small, compact, centrally located karyosome. The cytoplasm is usually described as finely granular with few ingested bacteria or debris in vacuoles. In the case of dysentery, however, RBCs may be visible in the cytoplasm, and this feature is diagnostic for E.histolytica.



(b) Cyst

Cysts range in size from 10-20µm. The immature cyst has inclusions namely; glycogen mass and chromatoidal bars. As the cyst matures, the glycogen completely disappears; the chromatoidals may also be absent in the mature cyst.



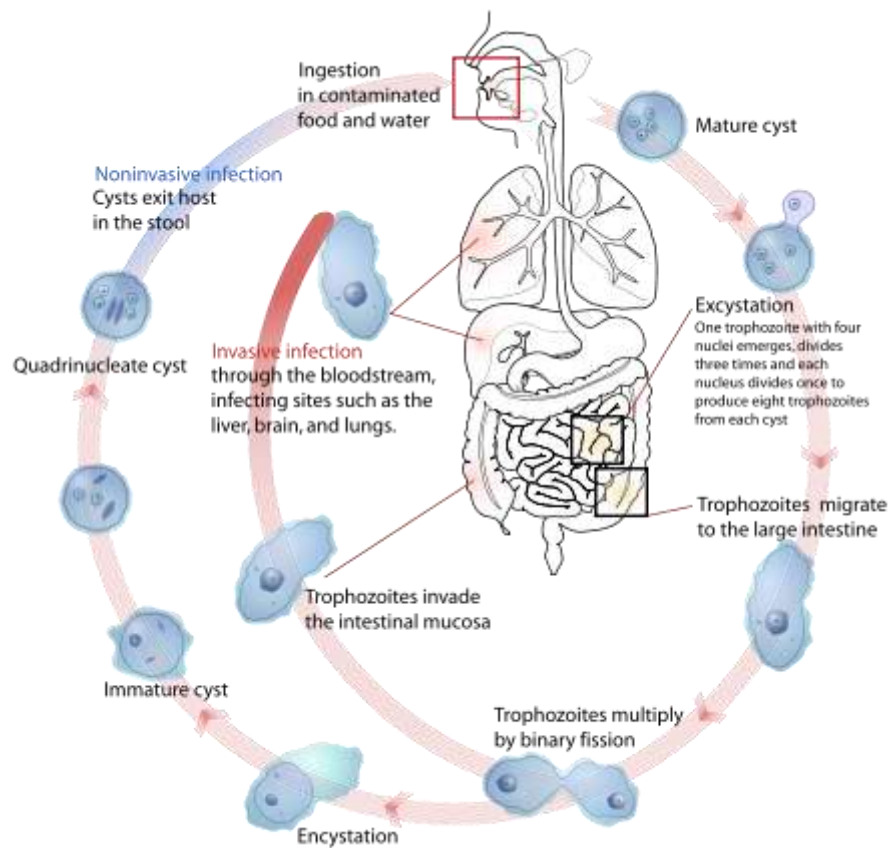
Life cycle

Intestinal infections occur through the ingestion of a mature quadrinucleate infective cyst, contaminated food or drink and also by hand to mouth contact. It is then passed unaltered through the stomach, as the cyst wall is resistant to gastric juice.

In terminal ileum (with alkaline pH), excystation takes place.

Trophozoites

being actively motile invade the tissues and ultimately lodge in the submucous layer of the large bowel. Here they grow and multiply by binary fission. Trophozoites are responsible for producing lesions in amoebiasis. Invasion of blood vessels leads to secondary extra intestinal lesions. Gradually the effect of the parasite on the host is toned down together with concomitant increase in host tolerance, making it difficult for the parasite to continue its life cycle in the trophozoite phase. A certain number of trophozoites come from tissues into lumen of bowel and are first transformed into pre-cyst forms. Pre-cysts secrete a cyst wall and become a uninucleate cyst. Eventually, mature quadrinucleate cysts form. These are the infective forms. Both mature and immature cysts may be passed in faeces. Immature cysts can mature in external environments and become infective.

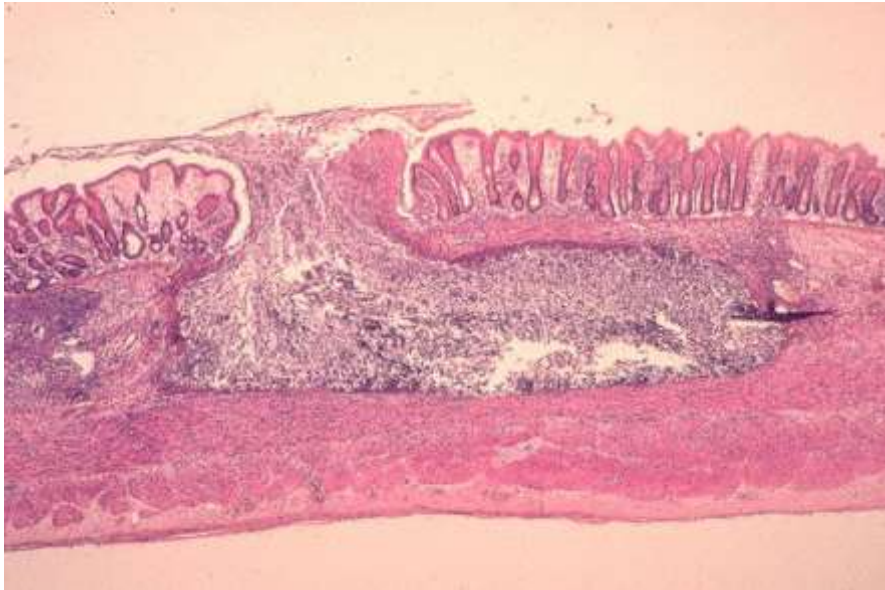

Pathogenesis

Trophozoites divide and produce extensive local necrosis in the large intestine. Invasion into the deeper mucosa with extension into the peritoneal cavity may occur. This can lead to secondary involvement of other organs, primarily the liver but also the lungs, brain, and heart. Extraintestinal amoebiasis is associated with trophozoites. Amoebas multiply rapidly in an anaerobic environment, because the trophozoites are killed by ambient oxygen concentration.

Extraintestinal amoebiasis

- Diagnosed by the use of scanning procedures for liver and other organs.
- Specific serologic tests, together with microscopic examination of the abscess material, can confirm the diagnosis



Histopathology of a typical flask-shaped ulcer of intestinal amebiasis

Epidemiology

E. histolytica has a worldwide distribution. Although it is found in cold areas, the incidence is highest in tropical and subtropical regions that have poor sanitation and contaminated water. About 90% of infections are asymptomatic, and the remaining produces a spectrum of clinical syndrome. Patients infected with *E. histolytica* pass non-infectious trophozoites and infectious cysts in their stools. Therefore, the main source of water and food contamination is the symptomatic carrier who passes cysts. Symptomatic amebiasis is usually sporadic. The epidemic form is a result of direct person-to-person faecal-oral spread under conditions of poor personal hygiene.

Clinical features

The outcome of infection may result in a carrier state, intestinal amebiasis, or extraintestinal amebiasis. Diarrhoea, flatulence, and cramping are complaints of symptomatic patients. More severe disease is characterised by the passing of numerous bloody stools in a day. Systemic signs of infection (fever, leukocytosis, rigors) are present in patients with extraintestinal amebiasis. The liver is primarily involved, because trophozoites in the blood are removed from the blood by the portal veins. The right lobe is most commonly involved, thus pain over the liver with hepatomegaly and elevation of the diaphragm is observed.

Genus and species	<i>Entamoeba histolytica</i>
Etiologic agent of:	<u>Amoebiasis</u> ; <u>amoebic dysentery</u> ; extraintestinal amoebiasis, usually amoebic liver abscess;); <u>amoeba cutis</u> ; <u>amoebic lung abscess</u> ("liver-colored sputum")
Infective stage	Tetranucleated cyst (having 4 nuclei)
Definitive host	Human
Portal of entry	Mouth
Mode of transmission	Ingestion of mature cyst through contaminated food or water
Habitat	Colon and cecum
Pathogenic stage	<u>Trophozoite</u>
Locomotive apparatus	Pseudopodia
Motility	Active, progressive and directional
Nucleus	'Ring and dot' appearance: peripheral chromatin and central karyosome
Mode of reproduction	Binary fission
Pathogenesis	Lytic necrosis (it looks like "flask-shaped" holes in Gastrointestinal tract sections (GIT))
Type of encystment	Protective and Reproductive
Lab diagnosis	Most common is direct fecal smear (DFS) and staining (but does not allow identification to species level); <u>enzyme immunoassay (EIA)</u> ; <u>indirect hemagglutination (IHA)</u> ; Antigen detection – monoclonal antibody; <u>PCR</u> for species identification. Sometimes only the use of a fixative (formalin) is effective in detecting cysts. Culture: From faecal samples - Robinson's medium, Jones' medium
Treatment	<u>Metronidazole</u> for the invasive trophozoites PLUS a luminal amoebicide for those still in the intestine. <u>Paromomycin</u> (Humatin) is the luminal drug of choice,
Trophozoite stage	
Pathognomonic/diagnostic feature	Ingested RBC; distinctive nucleus
Cyst Stage	
Chromatoidal body	'Cigar' shaped bodies (made up of crystalline ribosomes)
Number of nuclei	1 in early stages, 4 when mature

Balantidium coli

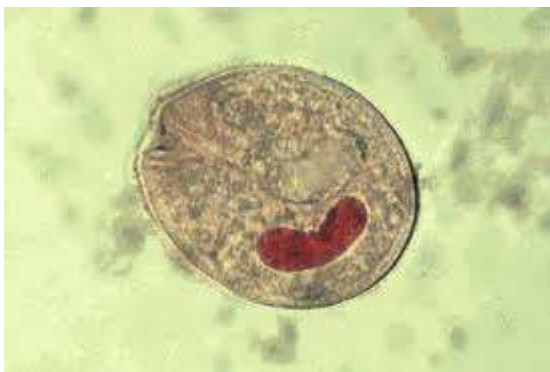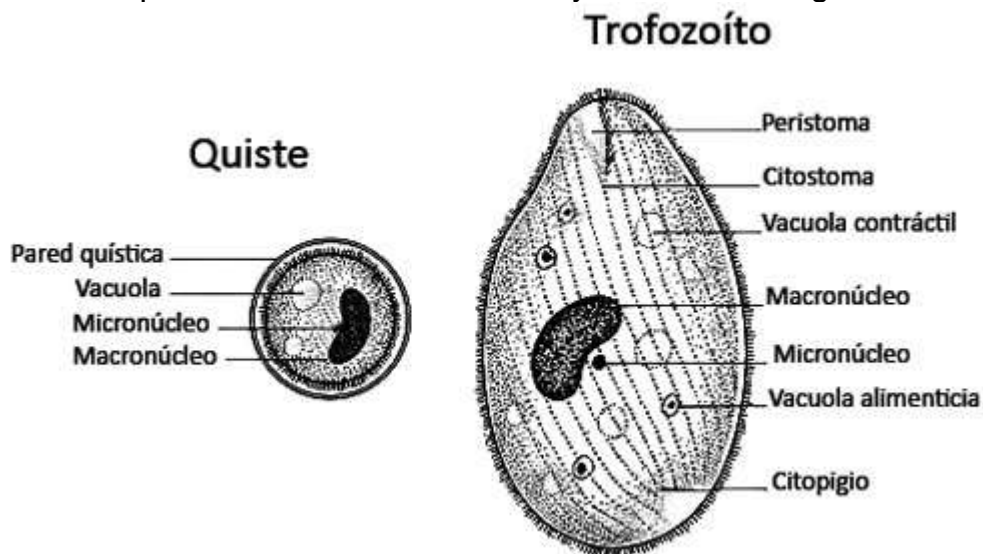
is a parasitic species of ciliate protozoan that causes the disease Balantidiasis. It is the only member of the ciliate phylum known to be pathogenic to humans. *Balantidium coli* is the largest protozoan parasite in humans and causes a disease called balantidiasis. It belongs to the ciliophora phylum and is the only protozoan ciliate to infect humans. It goes through two development phases; a cyst and a trophozoite.

Trophozoites

are 0.03–0.15 mm long and 0.025–0.12 mm wide. Their shape is either spherical or oblong. Their surface is covered with cilia and are able to move around. Trophozoites have both a micronucleus and a macronucleus, which both are normally visible. The macronucleus is bigger and sausage-shaped whereas the micronucleus is less notable.

Cysts

are spherical and 0.04–0.06 mm in diameter. They have a tough multilayered shell which protects them against stomach acid of the host, when ingested. They are usually destroyed at a pH lower than five (normal pH of a healthy stomach is about three). Some people are weakened by other diseases and thus the cysts are not killed. Unlike trophozoites, cysts cannot reproduce and do not have any cilia for moving.



Transmission

Balantidium is the only ciliated protozoan known to infect humans. Balantidiasis is a zoonotic disease and is acquired by humans via the feco-oral route from the normal host, the pig, where it is asymptomatic. Contaminated water is the most common mechanism of transmission.

Role in disease

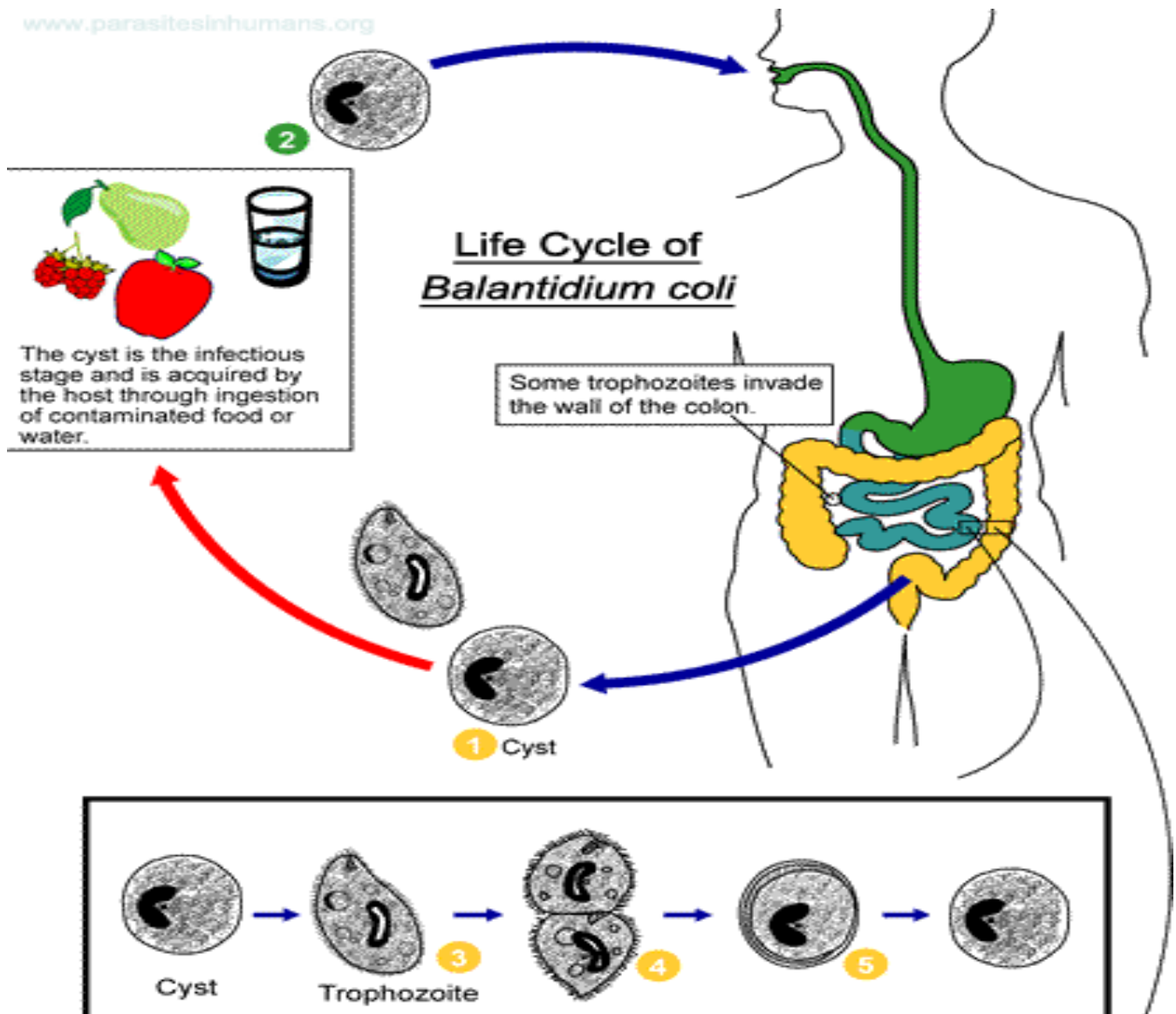
Balantidium coli lives in the cecum and colon of humans, pigs, rats and other mammals. It is not readily transmissible from one species of host to another because it requires a period of time to adjust to the symbiotic flora of the new host. Once it has adapted to a host species, the protozoan can become a serious pathogen, especially in humans. Trophozoites multiply and encyst due to the dehydration of feces.

Infection occurs when the cysts are ingested, usually through contaminated food or water. *Balantidium* infection in immunocompetent individuals is not unheard of, but it rarely causes a serious disease of the gastrointestinal tract. It can thrive in the gastrointestinal tract as long as there is a balance between the protozoan and the host without causing dysenteric symptoms. Infection most likely occurs in people with malnutrition due to the low stomach acidity or people with immune compromised systems.

In acute disease, explosive diarrhea may occur as often as every twenty minutes. Perforation of the colon may also occur in acute infections which can lead to life-threatening situations.

Life cycle

The life cycle of ***Balantidium coli*** begins, when a human eats food or water that has been contaminated with infective cysts. If the cysts survive through the stomach, trophozoites are formed in the small intestine. Trophozoites live in the cecum and the colon of the large intestine. They live and feed in the lumen but sometimes penetrate the mucosa. They multiply by transverse binary fission in the intestinal wall. Some trophozoites return to the lumen and encyst (transform into cysts) once the feces dry up. The cysts are formed either in the large intestine or outside of the body. If the feces get in contact with vegetables or drinking water, humans might ingest the cysts.



FLAGELLATES

Flagellates are unicellular microorganisms. Their locomotion is by lashing a tail-like appendage called a flagellum or flagella and reproduction is by simple binary fission. There are three groups of flagellates:

- Luminal flagellates *Giardia lamblia*

GIARDIASIS (lambliasis)

Etiology: *Giardia lamblia* (flagellate)

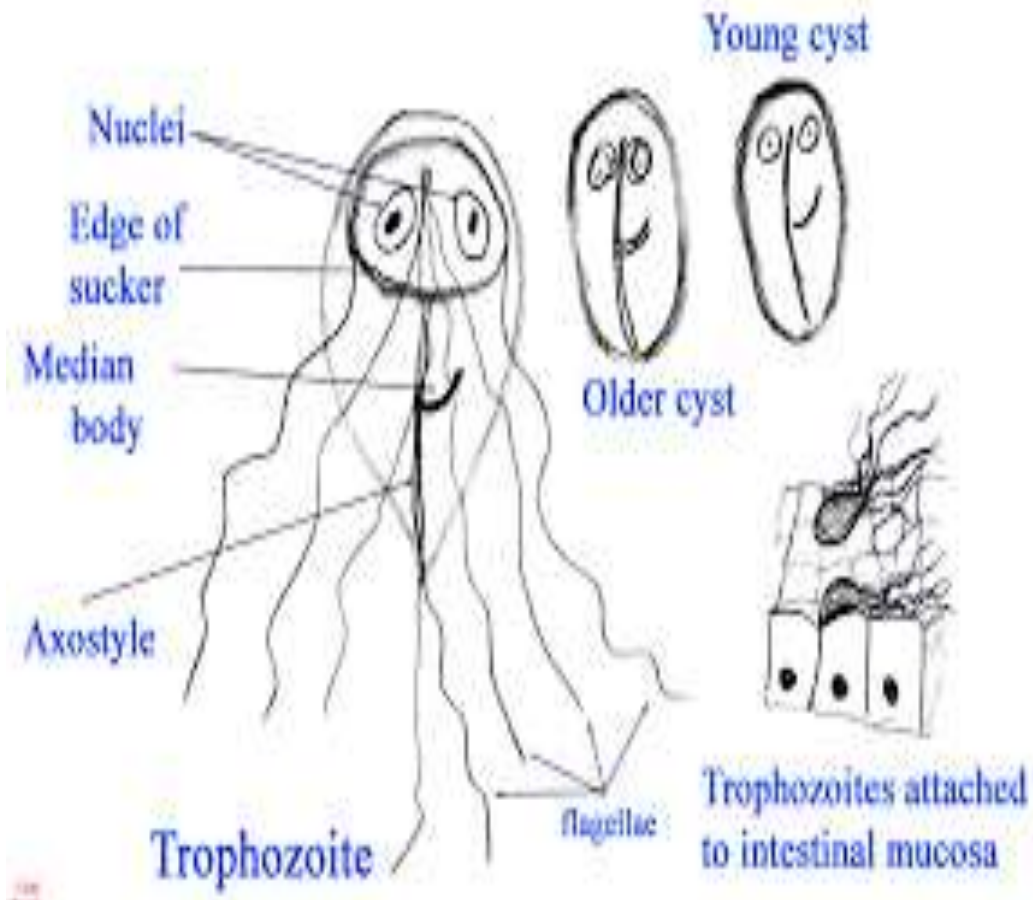
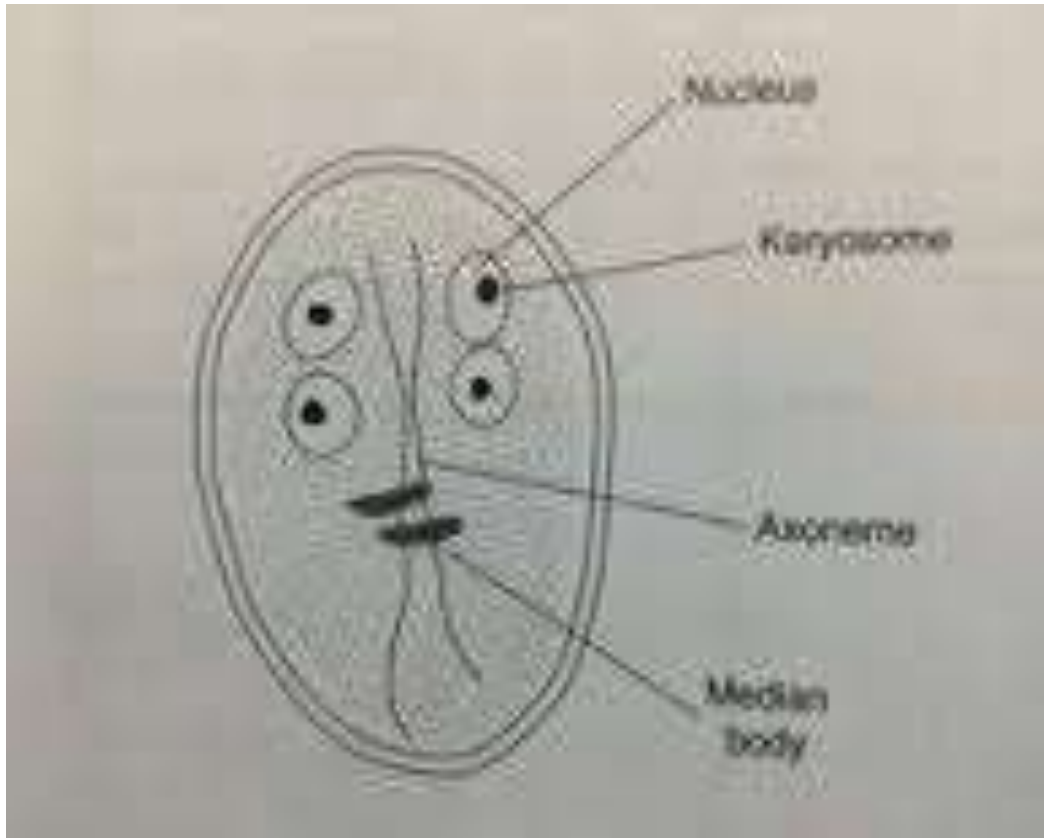
Epidemiology: It has worldwide distribution and is not uncommon in South Carolina. It is the most frequent protozoan intestinal disease in the US and the most common identified cause of water-borne disease associated with breakdown of water purification systems, outdoorsmanship, travel to endemic areas (Russia, India, Rocky Mountains, etc.) and day care centers.

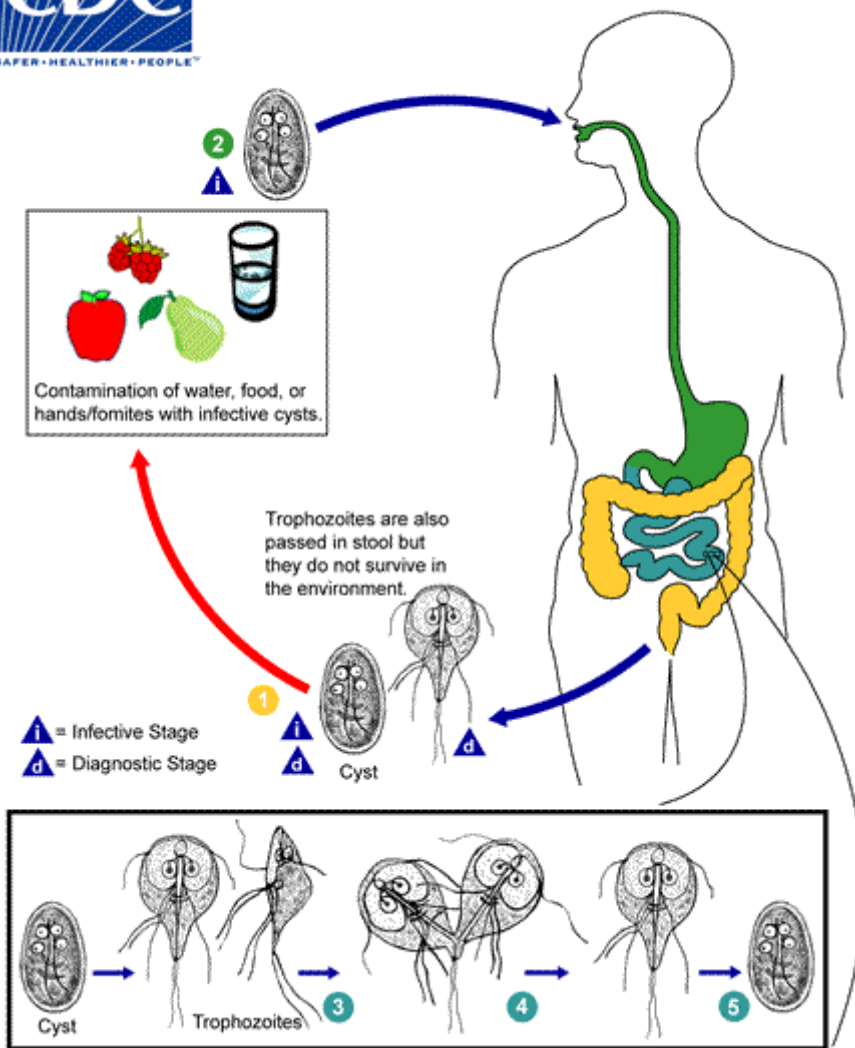
Morphology:

Trophozoite: It is 12-15 μ , half pear shaped with 8 flagella and, 2 axostyles arranged in a bilateral symmetry. There are two anteriorly located large suction discs. The cytoplasm contains two nuclei and two parabasal bodies (Figure 7).

Cyst: Giardia cysts are 9-12 μ ellipsoidal body with smooth well-defined wall. The cytoplasm contains 4 nuclei and many structures of the trophozoite.

Life cycle (Figure 6): Infection occurs by ingestion of cysts, usually in contaminated water. Decystation occurs in duodenum and trophozoites (trophs) colonize the upper small intestine where they may swim freely or attach to the sub-mucosal epithelium via the ventral suction disc. The free trophozoites encyst as they move down stream and mitosis takes place during the encystment. The cysts are passed in the stool. Man is the primary host although beavers, pigs and monkeys are also infected and serve as reservoirs.





Symptoms: The early symptoms include flatulence, abdominal distension, nausea and foul-smelling bulky, explosive, often watery, diarrhea. The stool contains excessive lipids but very rarely any blood or necrotic tissue. The more chronic stage is associated with vitamin B₁₂ malabsorption, disaccharidase deficiency and lactose intolerance.

Pathology: Covering of the epithelium by the trophozoite and flattening of the mucosal surface results in malabsorption of nutrients.

Diagnosis: Symptoms, history, epidemiology. Distinct from other dysentery due to lack of mucus, and blood in the stool, lack of increased PMN leukocytes in the stool and lack of high fever. Cysts in the stool and trophs (Figure 7) in duodenal content obtained using a string device (Enterotest[®]). Trophs must be distinguished from the nonpathogenic flagellate *Trichomona hominis*, an asymmetrical flagellate with an undulating membrane.

LUMINAL flagellates

TRICHOMONIASIS

Etiology: *Trichomonas vaginalis* (flagellate)

Epidemiology: It has a world-wide distribution; as low as 5% in normal females and as high as 70% among prostitutes and prison inmates.

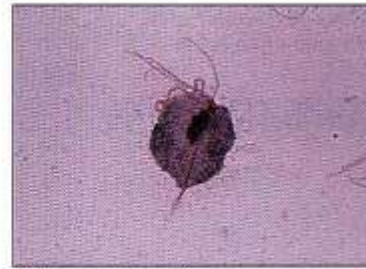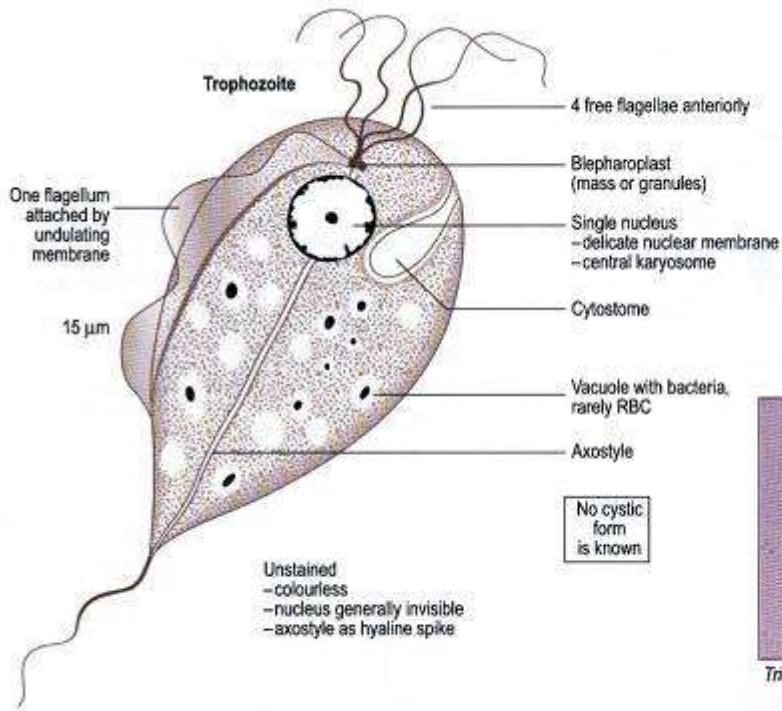
Morphology: Trophozoite: 15-18 μ , half pear shaped with a single nucleus, 4 anterior flagella and a lateral flagellum attached by an undulating membrane, 2 axostyles arranged asymmetrically (Figure 12). The organism does not encyst

Life cycle: *T. vaginalis* colonizes the vagina of women and the urethra (sometimes prostate) of men. Infection occurs primarily via sexual contact, although non-venereal infections are possible. The organism does not encyst and divides by binary fission which is favored by low acidity (pH>5.9; normal: 3.5-4.5). No non-human reservoir.

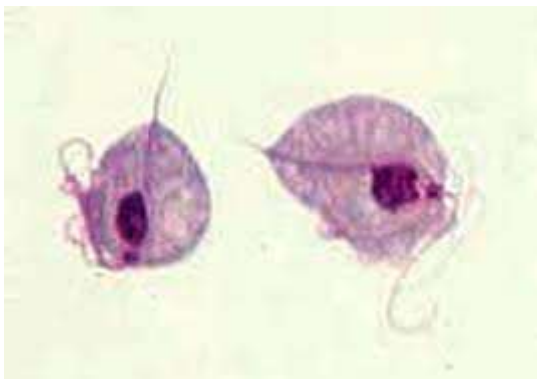Symptoms: *T. vaginalis* infection is rarely symptomatic in men, although it may cause mild urethritis or occasionally prostatitis. In women, it is often asymptomatic, but heavy infections in high pH environment may cause mild to severe vaginitis with copious foul-smelling yellowish, sometimes frothy discharge.

Diagnosis: Clinical suspicion may be confirmed by finding the organism in Geimsa stained smears (Figure 14) of vaginal discharge or, in difficult cases, cultivation of a swab sample in Diamond's medium. Trophozoites must be distinguished from the non-pathogenic flagellate *Trichomona hominis*

Treatment: Metronidazole (although teratogenic) is effective in both males and females. Vinegar douche may be useful. Personal hygiene and use of condom are helpful.



Trichomonas trophozoite



Blood Flagellates

LEISHMANIASIS

Etiology:

Several species of *Leishmania* are pathogenic for man: *L. donovani* causes visceral leishmaniasis (Kala-azar, black disease, dum dum fever); *L. tropica* (*L. t. major*, *L. t. minor* and *L. ethiopia*) cause cutaneous leishmaniasis (oriental sore, Delhi ulcer, Aleppo, Delhi or Baghdad boil); and *L. braziliensis* (also, *L. mexicana* and *L. peruviana*) are etiologic agents of mucocutaneous leishmaniasis (espundia, Uta, chiclero ulcer).

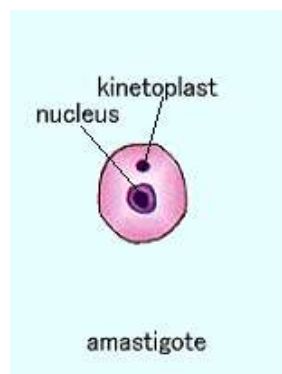
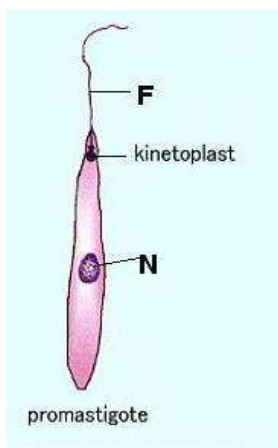
Epidemiology:

Leishmaniasis is prevalent world wide: ranging from south east Asia, Indo-Pakistan, Mediterranean, north and central Africa, and south and central America.

Parasite morphology

Two developmental stages are formed: amastigotes and promastigotes. The amastigotes are small spherical non-flagellated cells ranging from 2-4 μ m in diameter. The nucleus and kinetoplast are surrounded by small ring of vacuolated cytoplasm and the cells are among the smallest nucleated cells known. Promastigotes are thin elongate cells with an anterior kinetoplast and an emergent free flagellum. They are generally lance-like in shape and range in size from 5-14 μ m in length by 1.5-3.5 μ m in width. Different parasite species are generally not differentiated by morphological differences, but rather on the basis of geographical, biological and clinical features.

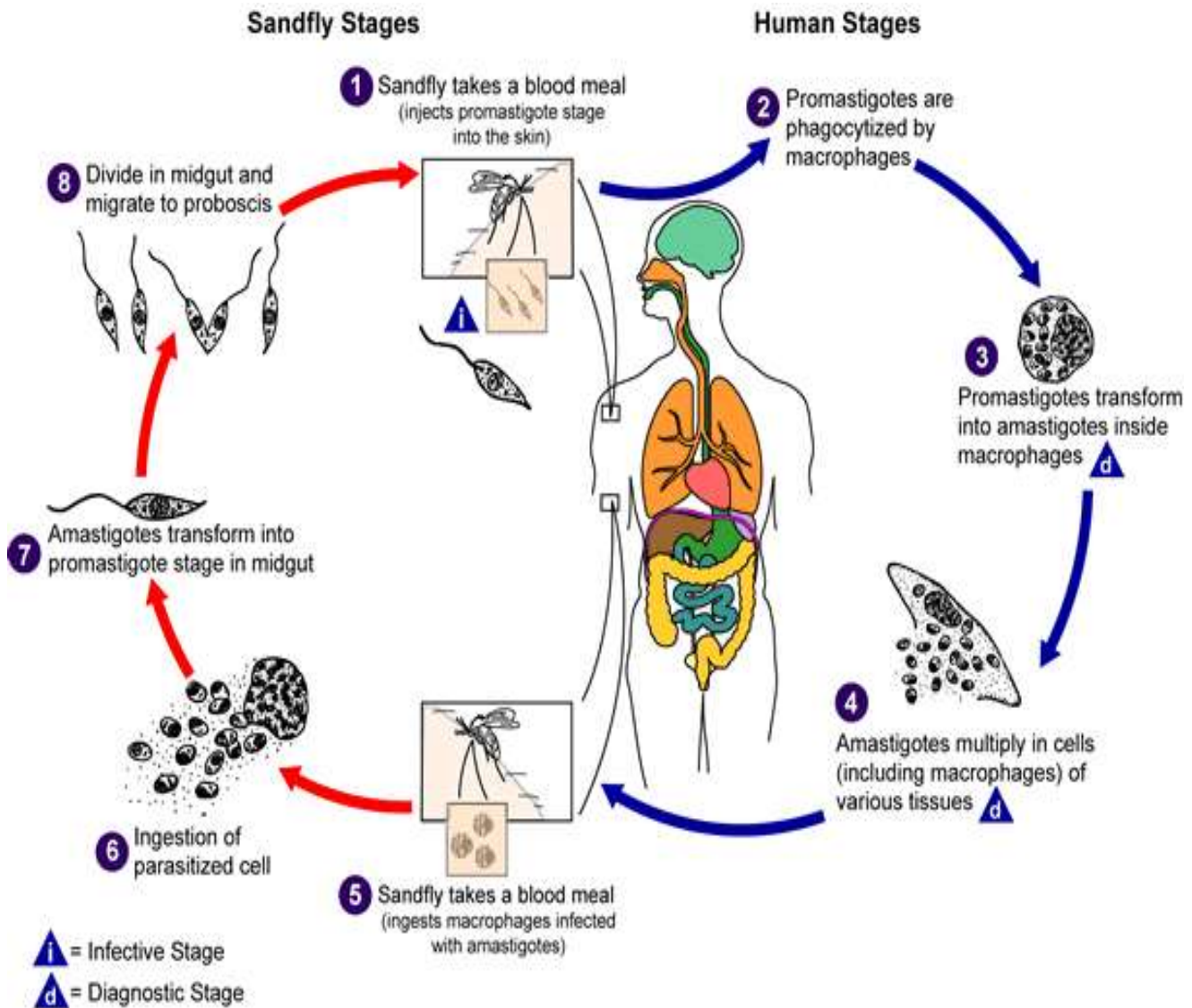
Promastigotes of Leishmania



Amastigote of Leishmania

Life cycle:

The organism is transmitted by the bite of several species of blood-feeding sand flies (*Phlebotomus*) which carries the promastigote in the anterior gut and pharynx. It gains access to mononuclear phagocytes where it transform into amastogotes and divides until the infected cell ruptures. The released organisms infect other cells. The sandfly acquires the organisms during the blood meal, the amastigotes transform into flagellate promastigotes and multiply in the gut until the anterior gut and pharynx are packed. Dogs and rodents are common reservoirs.



Site of infection:

Amastigotes invade macrophage cells of the reticuloendothelial and lymphoid systems of the skin, nasopharynx or viscera depending on the parasite species. The parasites survive within phagosomes but resist digestion by lysosomal enzymes. They multiply and grow, ultimately rupturing the host cell and releasing stages to infect new macrophages, including those which circulate in the blood (monocytes).

Mode of transmission:

All species are transmitted by small blood-sucking sandflies, notably *Phlebotomus* spp. in the Old World and *Lutzomyia* spp. in the New World. Only the females feed on blood. Amastigotes ingested during feeding transform in the midgut or hindgut into promastigotes which multiply by binary fission. The parasites migrate forward to the

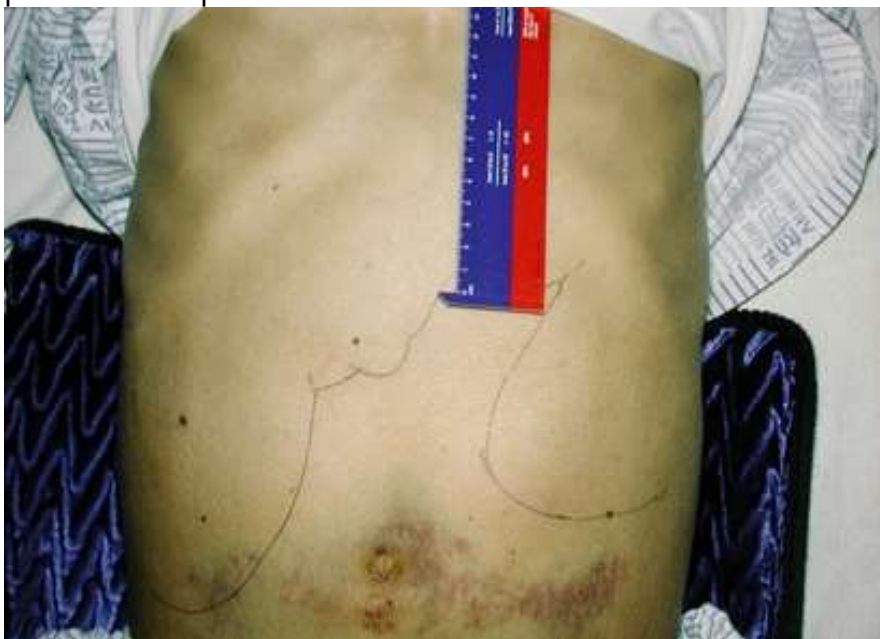foregut and proboscis where some become swept away by saliva into the bite site when the fly feeds.

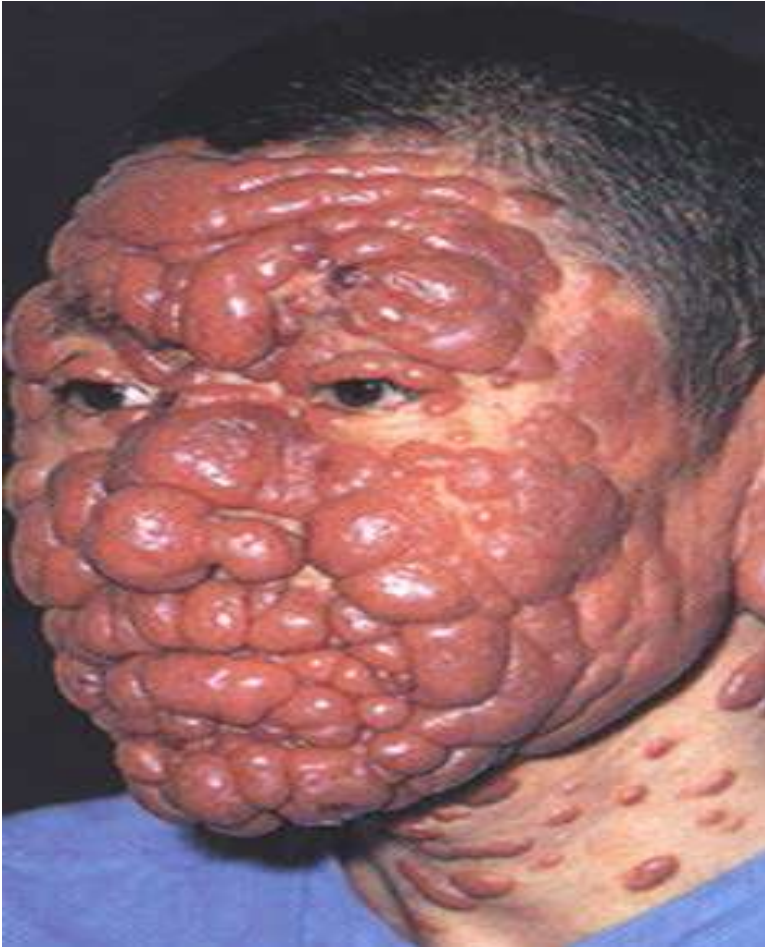Differential diagnosis:

Amastigotes may be detected microscopically in biopsy tissues, smears or secretions before or after culture. Parasites are best visualized using Giemsa's or Leishman's stains, and suitable culture media include conventional nutrient agar-blood mixtures. Serological tests have been developed but there are difficulties in distinguishing between recent and chronic infections and between infections by different parasite species, although a delayed-type hypersensitivity (DTH) skin test has shown good promise as a marker of cured symptomatic or asymptomatic visceral infection. Modern molecular characterization techniques have used the polymerase chain reaction (PCR) to amplify parasite DNA from host tissues.

Symptoms:

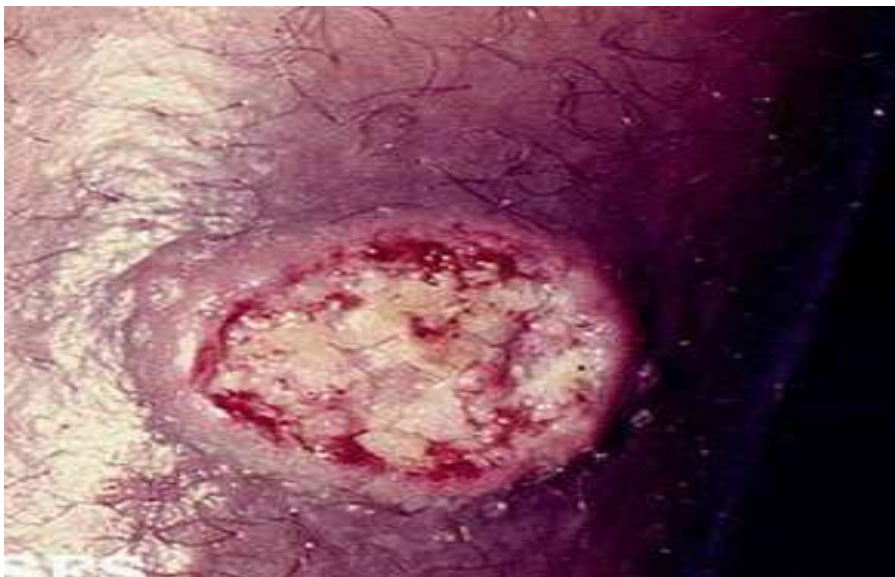
Visceral leishmaniasis (kala-azar, dum dum fever): *L. donovani*, organisms in visceral leishmaniasis are rapidly eliminated from the site of infection hence there is rarely a local lesion, although minute papules have been described in children. They localize and multiply in the mononuclear phagocytic cells of spleen, liver, lymph nodes, bone marrow, intestinal mucosa and other organs. 1-4 months after infection there is occurrence of fever, with a daily rise to 102-104 degrees F, accompanied with chills and sweating. Spleen and liver progressively become enlarged. With progression of the disease, skin develops hyperpigmented granulomatous areas (kala-azar: black disease). Chronic disease renders patients susceptible to other infections. Untreated disease results in fatal termination



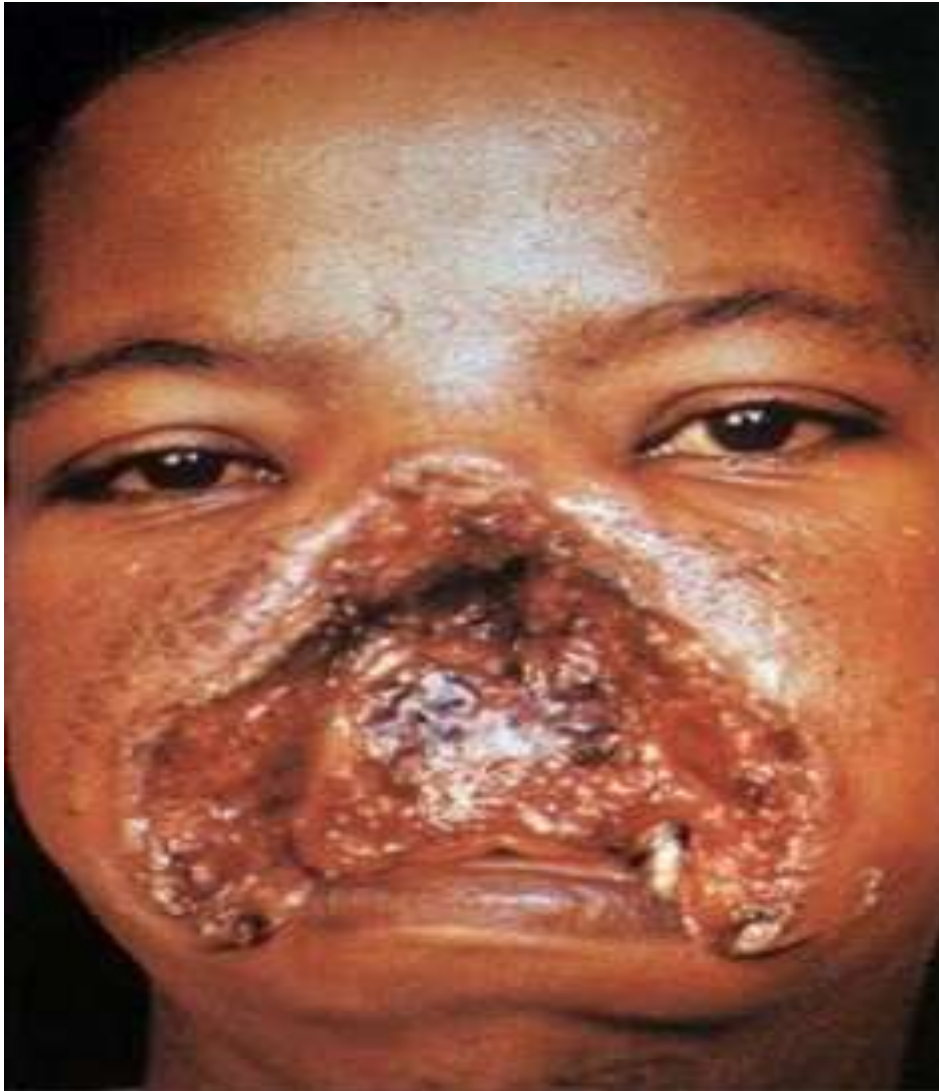

Post kala azar

Cutaneous leishmaniasis (Oriental sore, Delhi ulcer, Baghdad boil): In cutaneous leishmaniasis, the organism (*L. tropica*) multiplies locally, producing of a papule, 1-2 weeks (or as long as 1-2 months) after the bite, which gradually grows to form a relatively painless ulcer. The center of the ulcer encrusts while satellite papules develop at the periphery. The ulcer heals in 2-10 months even if untreated but leaves a disfiguring scar. The disease may disseminate in the case of a depressed immune function



Mucocutaneous leishmaniasis (espundia, Uta, chiclero): The initial symptoms of mucocutaneous leishmaniasis are the same as those of cutaneous leishmaniasis, except that in this disease the organism can metastasize and the lesions spread to mucoid (oral, pharyngeal and nasal) tissues and lead to their destruction and hence severe deformity. The organisms responsible are **L. braziliensis**, **L. mexicana** and **L. peruviana**.



Treatment and Control:

Sodium stibogluconate (Pentostam) is the drug of choice. Pentamidine isethionate is used as an alternative. Control measure involves the vector control and avoidance. Immunization has not been effective.

Trypanosoma brucei

is a species of parasitic [protozoan](#) belonging to the genus [Trypanosoma](#). It causes [African trypanosomiasis](#), known also as sleeping sickness in humans and [nagana](#) in animals. *T. brucei* has traditionally been grouped into three subspecies: *T. b. brucei*, *T. b. gambiense* and *T. b. rhodesiense*. The latter two are typically parasites of humans, while the first is that of animals. Only rarely can the *T.b.brucei* infect a human.^[1]

T. brucei is transmitted between mammal hosts by an [insect vector](#) belonging to the species of [tsetse fly](#). Transmission occurs by biting during the insect's blood meal. The parasites undergo complex morphological changes as they move between insect and mammal over the course of their [life cycle](#). The mammalian bloodstream forms are notable for their [variant surface glycoprotein](#) (VSG) coats, which undergo remarkable [antigenic variation](#), enabling persistent evasion of host adaptive immunity and chronic infection. *T. brucei* is one of only a few pathogens that can cross the [blood brain barrier](#).^[2] There is an urgent need for the development of new drug therapies, as current treatments can prove fatal to the patient.^[3]

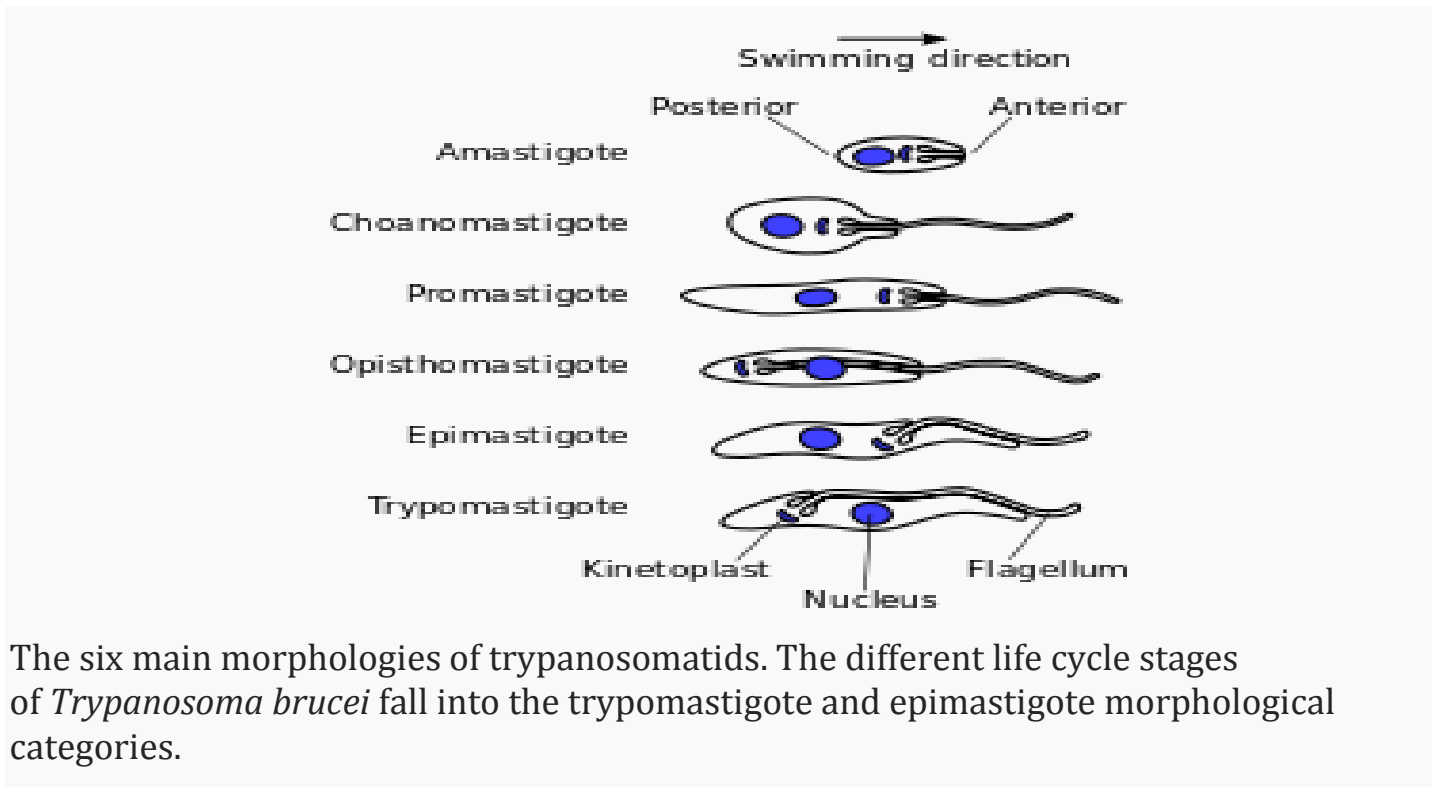
Whilst not historically regarded as *T. brucei* subspecies due to their different means of transmission, clinical presentation, and loss of [kinetoplast](#) DNA, genetic analyses reveal that [T. equiperdum](#) and [T. evansi](#) are evolved from parasites very similar to *T. b. brucei*, and are thought to be members of the *brucei* [clade](#).

T. brucei comprises a species complex that includes:

- *T. brucei gambiense* — Causes slow onset chronic trypanosomiasis in humans. Most common in central and western Africa, where humans are thought to be the primary [reservoir](#).^[7]
- *T. brucei rhodesiense* — Causes fast onset acute trypanosomiasis in humans. Most common in southern and eastern Africa, where game animals and livestock are thought to be the primary [reservoir](#).^[7]
- *T. brucei brucei* — Causes [animal African trypanosomiasis](#), along with several other species of [trypanosoma](#). *T. b. brucei* is not infective to humans due to its susceptibility to lysis by trypanosome lytic factor

T. brucei is a typical unicellular [eukaryotic cell](#), and measures 8 to 50 µm in length. It has an elongated body having a streamlined and tapered shape. Its cell membrane (called pellicle) encloses the cell organelles, including the [nucleus](#), [mitochondria](#), [endoplasmic reticulum](#), [Golgi apparatus](#), and [ribosomes](#). In addition, there is an unusual organelle called the [kinetoplast](#), which is made up of numerous circular DNA ([mitochondrial DNA](#)) and functions as a single large mitochondrion. The kinetoplast lies near the [basal body](#) with which it is indistinguishable under microscope. From the basal body arises a single [flagellum](#) that run towards the anterior end. Along the body surface, the flagellum is attached to the cell membrane forming an undulating membrane. Only the tip of the

flagellum is free at the anterior end.^[9] The cell surface of the bloodstream form features a dense coat of variant surface glycoproteins (VSGs) which is replaced by an equally dense coat of **procyclins** when the parasite differentiates into the procyclic in the tsetse fly midgut.



The six main morphologies of trypanosomatids. The different life cycle stages of *Trypanosoma brucei* fall into the trypomastigote and epimastigote morphological categories.

Trypanosomatids show several different classes of cellular organisation of which two are adopted by *Trypanosoma brucei* at different stages of the life cycle:^[9]

- **Epimastigote**, which is found in tsetse fly. Its kinetoplast and basal body lie anterior to the nucleus, with a long flagellum attached along the cell body. The flagellum starts from the centre of the body.
- **Trypomastigote**, which is found in mammalian hosts. The kinetoplast and basal body are posterior of nucleus. The flagellum arises from the posterior end of the body.

Trypanosoma Brucei flagellar structure.

These names are derived from the **Greek mastig-** meaning **whip**, referring to the trypanosome's whip-like flagellum. The trypanosome flagellum has two main structures. It is made up of a typical flagellar axoneme which lies parallel to the paraflagellar rod, a lattice structure of proteins unique to the **kinetoplastida**, **euglenoids** and **dinoflagellates**.

The microtubules of the flagellar **axoneme** lie in the normal 9+2 arrangement, orientated with the + at the anterior end and the - in the basal body. The a cytoskeletal structure extends from the basal body to the kinetoplast. The flagellum is bound to the

cytoskeleton of the main cell body by four specialised microtubules, which run parallel and in the same direction to the flagellar tubulin.

The flagellar function is twofold — locomotion via oscillations along the attached flagellum and cell body, and attachment to the fly gut during the procyclic phase.

T. brucei completes its life cycle between tsetsefly (of the genus *Glossina*) and mammalian hosts, including humans, cattle, horses, and wild animals.

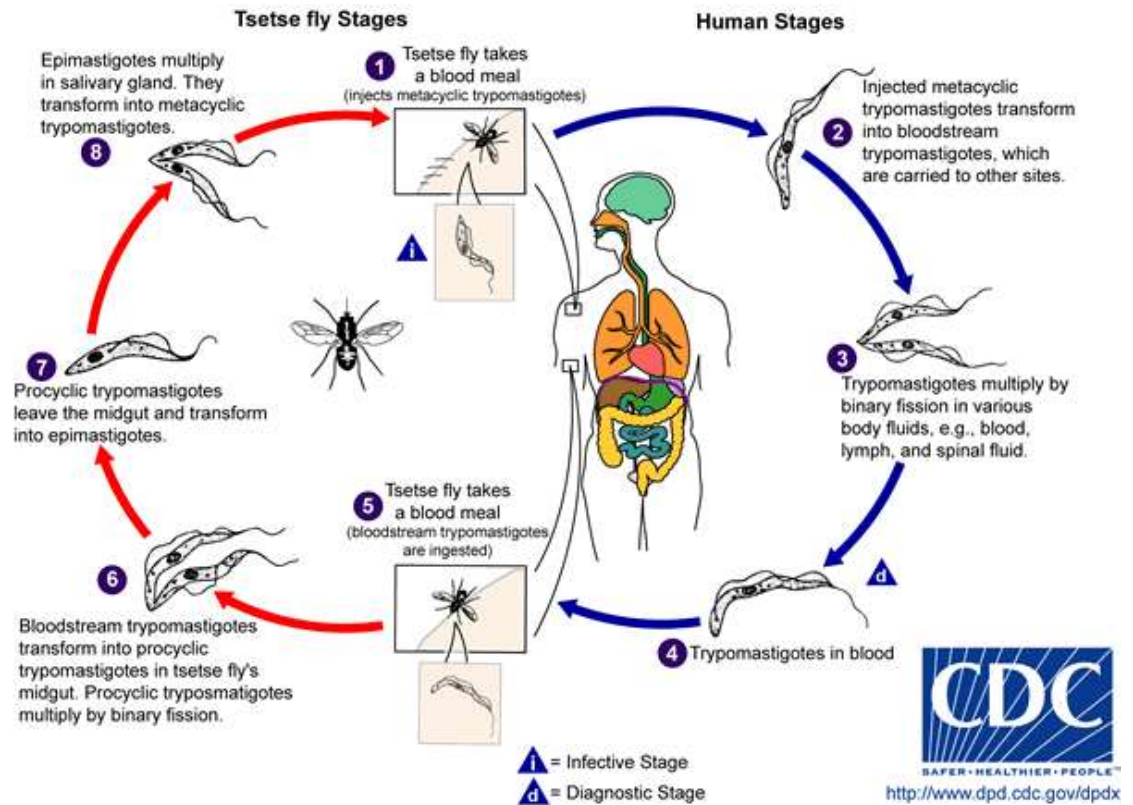
In mammalian host

Infection occurs when a vector tsetse fly bites a mammalian host. The fly injects the metacyclic trypomastigotes into the skin tissue. The trypomastigotes enter the **lymphatic system** and into the bloodstream. The initial trypomastigotes are short and stumpy. Once inside the bloodstream, they grow into long and slender forms. Then, they multiply by **binary fission**. The daughter cells then become short and stumpy again. The long slender forms are able to penetrate the blood vessel endothelium and invade extravascular tissues, including the **central nervous system (CNS)**.

Sometimes, wild animals can be infected by the tsetsefly and they act as reservoirs. In these animals, they do not produce the disease, but the live parasite can be transmitted back to the normal hosts.

In tsetse fly

The short and stumpy trypomastigotes are taken up by tsetse fly during blood meal. The trypomastigotes enter the midgut of the fly where they become procyclic trypomastigotes. These rapidly divide to become epimastigotes. The epimastigotes migrate from the gut via the proventriculus to the **salivary glands** where they get attached to the salivary gland epithelium. In the salivary glands, some parasites detach and undergo transformation into short and stumpy trypomastigotes. These become the infective metacyclic trypomastigotes. They are injected into the mammalian host along with the saliva on biting. Complete development in the fly takes about 20 days



Pathogenesis of African Trypanosomiasis

PRIMARY STAGE.

When metacyclic trypomastigotes are introduced subcutaneously and multiply.

In 2-3 days there is itching, swelling, pain and redness, and after 6 days a trypanosomal chancre may develop at the bite site. This is considered by most to be an innocent boil and is disregarded.

BLOOD STAGE

The earliest sign of a generalized infection is fever; there may also be malaise, headache and pains in the joints. Five to 12 days after infection trypanosomes are found in the bloodstream. They are scanty in *T. gambiense*, and more abundant i.e. 10^5 /ml in *T. rhodesiense*. Trypanosomes also enter the lymphatics and there is lymphadenopathy. Especially characteristic in *T. gambiense* is the enlarged cervical lymph nodes, called Winterbottom's sign. The influx of B-cells results in lymph node enlargement and the lysis of trypanosomes release toxic materials that stimulate macrophages to release

tumor necrosis factor (TNF, also called cachectin) and this produce cachexia. The release of trypanosome toxic factors and lymphokines gives rise to a cyclic (or relapsing) fever with an approximate cycle of 7-10 days.

LATE STAGE

In the Rhodesian form there is a rapid illness with invasion of the CNS via lymphatics within a few weeks. Patients may die of myocarditis even before the CNS is invaded. In the Gambian form the disease progresses in a more insidious fashion with personality changes, insomnia or irritability signaling invasion of the CNS. CNS involvement may not occur until one or more years after infection. Inflammatory changes lead to a demyelinating meningoencephalitis; there is cerebral edema, hemorrhages, pericarditis, and anemia. The encephalopathy leads to apathy, somnolence and coma. Death is usually caused by intercurrent infections such as pneumonia.

The anemia seen in trypanosomiasis may be due to coating of host red blood cells with trypanosome surface coat proteins and reaction with antibody to the variant antigens; demyelination may result from cross reactivity of anti-galactocerebroside autoantibodies with a proteolipidic epitope of *T. brucei*. In experimental infections, toxic metabolites of aromatic (ring) amino acids such as tryptophan, phenylalanine and tyrosine can produce anesthetic effects, damage blood vessels, induce temperature changes, immunosuppression and somnolence.

Symptoms/Pathology

Infection with *Trypanosoma cruzi* usually begins with a lesion at the site of inoculation called a chagoma. The infected person may not show signs of infection or may exhibit fever, anorexia, or heart problems. If symptoms in this early, acute stage are present, they tend to disappear in 2-3 months as the person enters an asymptomatic chronic stage that may last for years or decades. Symptomatic chronic disease, including pathology of the heart and digestive tract, weight loss and pulmonary infections may then develop and can be fatal.

PATHOLOGIC FINDINGS

The natural history of infection consists of acute and chronic phases

In general, the acute phase consists of parasitemia, generally with nonspecific or no symptoms, and typically lasts 8 to 12 weeks; in a minority of patients, there is inflammation and swelling at the site of inoculation (chagoma). The chronic phase typically begins with a long period of latency (indeterminate form) characterized by lack

of objective evidence of organ damage . An estimated 30 percent of these individuals progress over a period of years to decades to clinically evident chronic disease; heart disease develops more commonly than gastrointestinal disease. The clinical aspects of these phases are outlined separately.

Acute phase — Organ damage during the acute phase occurs as a result of high grade parasitemia and direct tissue parasitism. Affected sites typically include the heart, gastrointestinal tract (mainly esophagus and colon), and central nervous system. Lymphadenopathy, hepatomegaly, and splenomegaly are markers of widespread immunologic reaction, which leads to control of the acute infection but probably exacerbates tissue damage. Histopathology during the acute phase demonstrates intense parasitism in every involved organ system, with prominent inflammatory changes in the vicinity of ruptured infected cells .

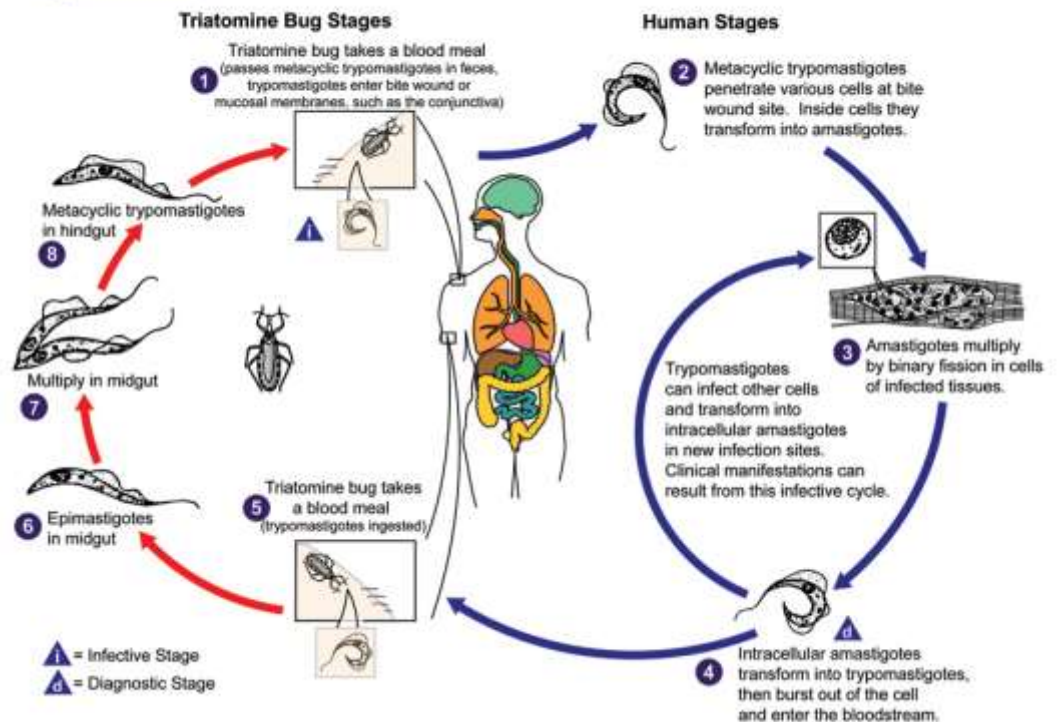
All four cardiac chambers may become dilated, and pericardial effusion is common. Myocarditis is intense and diffuse with myocyte necrosis, interstitial edema, vascular dilation, and mononuclear and polymorphonuclear infiltration (). The inflammatory process may extend to the endocardium, resulting in thrombus formation. Involvement also includes the conduction system as well as the intramural and extracardiac neuronal ganglia.

The life cycle of *T. cruzi* is relatively complex, as there are different forms of the parasite in both the insect vector (Reduviid bugs) and mammals (including humans but also many other species); all appear to be well adapted to their respective environments, maximizing transmission potential and/or host immune evasion and, hence, long-term parasite survival.

T. cruzi cycles between two biologically and morphologically distinct stages in mammals. The trypomastigotes circulate in the blood, where they do not divide, but can enter various types of cells in the host. Once inside a host cell, *T. cruzi* trypomastigotes move to the cytoplasm and transform into a more rounded form without a flagellum - known as amastigotes. Amastigotes are the dividing form of *T. cruzi* in mammals.

Following multiple rounds of division over 4-5 days, all within the cytoplasm of the host cells, amastigotes convert back to trypomastigotes and leave the now dying host cell. These released trypomastigotes can then infect other host cells locally or enter the blood circulation where they may invade cells in other tissues in the body or be transmitted to the insects during the course of its feeding. In the insect, these trypomastigotes convert to rapidly dividing epimastigotes which remain in the insect gut. Ultimately, after weeks of replication in the gut, the epimastigotes differentiate into metacyclic trypomastigotes, a stage similar to the blood-form trypomastigotes and capable of initiating infection in mammals.

Trypanosomiasis, American (Chagas disease) (*Trypanosoma cruzi*)



Toxoplasma Gondii

Toxoplasma gondii is a microscopic protozoa that causes a disease called toxoplasmosis. The disease is found all over the world. Some estimates suggest that over 30 % of human population is infected. For example, in Germany and France most people carry the parasite, whereas in South Korea it is quite rare. More than 60 million people in the United States are said to be infected. Toxoplasmosis is usually asymptomatic, because our immune system keeps the parasite from causing illness. The disease is more problematic for pregnant women and people who have weakened immune systems. Cats are the primary host and humans and other warm blooded animals are just intermediate hosts. In this sense *Toxoplasma gondii* is not a pure human parasite.

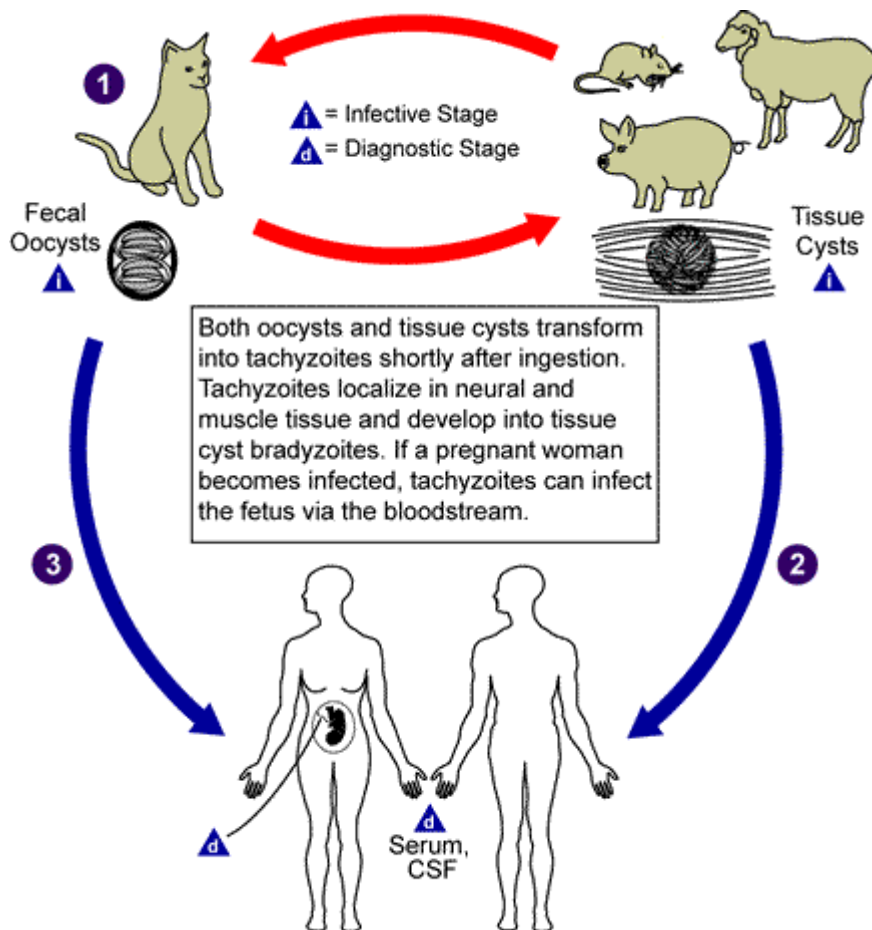
Toxoplasma gondii is known to **change the host's behaviour**. Studies show the capability for the parasite to make rats fearless near cats. This indicates the evolutionary need for *Toxoplasma gondii* to get inside felines. When a rat is eaten by a cat the parasite gets inside the primary host. There have been a few studies with humans, too. Some results indicate a strong correlation between schizophrenia and toxoplasmosis. According to some studies women with toxoplasmosis are more likely to cheat their husbands. Men with the parasite have shown to be more aggressive. Infected humans also have slower reaction times.

Humans get infected by:

- blood transfusion or organ transplantation (very rare)
- consuming undercooked, infected meat (especially lamb, pork and venison)
- ingesting water, soil (for example, putting dirty fingers in your mouth) or anything else that has been contaminated with cat feces
- mother-to-child transmission. A pregnant woman, who has just been infected with *Toxoplasma gondii* can pass the infection to her unborn baby (congenital infection). She might not have any symptoms, but the unborn child might suffer and develop disease.

The life cycle of *Toxoplasma gondii*

starts, when oocysts (resting form of the parasite) exit the primary host (cat) in the feces. Millions of oocysts are shed for as long as three weeks after infection. Oocysts sporulate and become infective within a few days in the environment. The oocysts are found only in the feces of domestic and wild cats. Birds, humans and other intermediate hosts get infected after ingesting water or food contaminated with the cat feces. (Healthy cats can get infected this way, too.) In the gut oocysts transform into tachyzoites which are about 4–8 μm long and 2–3 μm wide. They travel to other parts of the body via bloodstream and further develop into tissue cyst bradyzoites in muscle and neural tissue. Cysts are about 5–50 μm in diameter. They are commonly found in skeletal muscles, brain, myocardium and eyes where they can remain many decades. If a cat (or a human) eats the intermediate host, the tissue cysts get ingested and the parasite activates in the small intestine.



Healthy people who become infected often do not have **symptoms** because their immune system keeps the parasite from causing sickness. 10–20 % of patients develop sore lymph nodes, muscle pains and other minor symptoms that last for several weeks and then go away (**acute toxoplasmosis**). The parasites remain in the body as tissue cysts (bradyzoites) and reactivate, if the person becomes immunosuppressed by other diseases or by immunosuppressive drugs.

Usually if a woman has been infected before becoming pregnant, the unborn baby is safe because the mother has developed immunity. If a woman is pregnant and becomes infected with toxoplasmosis during or right before pregnancy, she can transmit the disease to her unborn child (**congenital transmission**). The earlier the transmission occurs the bigger the effects. Then again, the longer the pregnancy goes on, the more likely is the infection going to occur. This has something got to do with the penetrability of the placenta.

Symptoms might include:

- miscarriage or stillborn baby

- baby born with signs of toxoplasmosis (for example, abnormal enlargement or smallness of the head)
- baby with brain or eye damage.

Usually the babies have no symptoms initially, but can develop mental disability, vision loss (ocular toxoplasmosis) and seizures later in life.

Eye disease can be caused by congenital toxoplasmosis or infection after birth or rarely from acute toxoplasmosis as an adult. Eye lesions from congenital infection are often not present at birth but occur in 20–80 % of infected individuals, when they reach adulthood. However, in the U.S. less than 2 % of persons infected after birth develop eye lesions. Eye infection leads to an acute inflammatory lesion of the retina, which leaves retinochoroidal scarring. Symptoms of acute **ocular toxoplasmosis** include:

- blurred or reduced vision
- eye pain
- redness of the eye
- sensitivity to light (photophobia)
- tearing of the eyes.

The eye disease can reactivate later in life causing more damage to the retina. If the central structures of the retina are damaged, a progressive vision loss may follow.

People with weakened immune systems may develop central nervous system disease, brain lesions, pneumonitis or retinochoroiditis among other risks. For example, people with AIDS and renewed toxoplasmosis can have symptoms that include:

- confusion
- fever
- headache
- nausea
- poor coordination
- seizures.

If latent (chronic) toxoplasmosis reactivates in immunocompromised pregnant women who were infected before their pregnancy, it might cause congenital infection to the baby.

Toxoplasmosis diagnosis

is typically made by serologic tests by detecting immunoglobulin antibodies within several weeks of infection. Your health care provider examines your blood sample to find *Toxoplasma*-specific IgA, IgG or IgM antibodies. Living parasites can be also found in

the sample (blood, cerebrospinal or other body fluids) but the process is more difficult and thus not usually used. Direct observation of the parasite is possible in cerebrospinal fluid (CSF), stained tissue sections or other biopsy samples but these techniques are used less frequently due to their difficulty. A test that measures IgG determines if a person has been infected. Sometimes it is necessary to determine the time of the infection especially if the person is pregnant. For this IgM is detected along with IgG avidity test. Molecular techniques are used for detecting *Toxoplasma gondii* DNA in the amniotic fluid in cases of congenital transmission (mother-to-child transmission). Ocular toxoplasmosis diagnosis is usually based on symptoms, appearance of lesions in the eye, serologic testing and course of the infection. Serologic tests can be unreliable in immunosuppressed patients.

Toxoplasmosis can be **treated** with combinations of pyrimethamine with either trisulfapyrimidines or sulfadiazine, plus folinic acid in the form of leucovorin calcium to protect the bone marrow from the toxic effects of pyrimethamine. If this treatment causes hypersensitivity reaction, then pyrimethamine and clindamycin can be used instead. If these drugs are not available, then a combination of sulfamethoxazole and trimethoprim can be used. Pregnant women and babies can be treated but *Toxoplasma gondii* cannot be eliminated completely. The parasites can remain within tissue cells in a less active stage (cyst) in locations difficult for the medication to get to. A drug called spiramycin is recommended during the first four months whereas sulfadiazine/pyrimethamine and folinic acid for women that have been pregnant for more than four months. PCR (a method to discover parasite DNA) is often performed on the amniotic fluid to find out if the infant is infected. If the infant is likely to be infected, then treatment is done with drugs such as sulfadiazine, pyrimethamine and folinic acid. Congenitally infected babies are treated with sulfonamide and pyrimethamine. Treatment for persons with ocular disease depends on the size of the eye lesion, the characteristics (acute or chronic) and the location of the lesion. Persons with compromised immune systems (such as AIDS patients) need to be treated until their health improves significantly.

Plasmodium,

commonly known as the **malaria parasite**, is a large [genus](#) of [parasitic protozoa](#). As with some other genera of clinically important [microorganisms](#), the genus name also yields a common noun; thus species of the genus are known as **plasmodia**. Infection with plasmodia is known as [malaria](#), a deadly disease widespread in the [tropics](#).

The parasite always has two hosts in its [life cycle](#): a [Dipteran insect host](#) and a [vertebrate](#) host. Sexual reproduction always occurs in the insect [definitive host](#) (also known as the disease [vector](#)).

The life-cycle is complex, involving a sequence of different stages both in the vector and the vertebrate host. These stages include [sporozoites](#), which are injected by the insect vector into the vertebrate host's blood; latent hypnozoites, which may rest undetected in the liver for up to 30 years; merozoites and merozoites, which infect the red cells ([erythrocytes](#)) of the blood; [trophozoites](#), which grow in the red cells, and [schizonts](#), which divide in red blood cells. [Schizonts](#) produce merozoites, which leave to infect more red cells. The sexual forms, gametocytes, are taken up by other insect hosts during feeding. Gametocytes develop into [gametes](#) in the insect midgut, and then [fertilize](#) each other to form motile [zygotes](#), which escape the gut. Zygotes grow into new sporozoites, which move to the insect's salivary glands. Sporozoites are injected into vertebrate hosts during insect feeding, thus completing the cycle of infection.

The genus *Plasmodium* was first described in 1885. It now contains about 200 species divided into several subgenera; as of 2006 the [taxonomy](#) was shifting, and species from other genera are likely to be added to *Plasmodium*. At least ten species infect humans; other species infect other animals, including [birds](#), [reptiles](#) and [rodents](#), while 29 species infect non-human [primates](#). The parasite is thought to have originated from [Dinoflagellates](#), photosynthetic protozoa.

The most common forms of human malaria are caused by [Plasmodium falciparum](#), [P. vivax](#), [P. ovale](#), [P. knowlesi](#), and [P. malariae](#). *P. falciparum*, common in [sub-Saharan Africa](#), and *P. knowlesi*, common in [Southeast Asia](#), are especially dangerous.

The life cycle of *Plasmodium*

is very complex. [Sporozoites](#) from the saliva of a biting female mosquito are transmitted to the skin from where they migrate to enter either the blood or the lymphatic system of the recipient. The sporozoites entering the blood are transported to the [liver](#) and invade [hepatocytes](#). The latent or dormant stage of the *Plasmodium* parasite in the liver is called the hypnozoite.

The development from the hepatic stages to the erythrocytic stages has been obscure. In 2006^[4] it was shown that the parasite buds off the hepatocytes in merozoites containing hundreds or thousands of merozoites. These merozoites have been subsequently shown^[5] to lodge in the pulmonary capillaries and to disintegrate there slowly over 48–72 hours releasing merozoites. Erythrocyte invasion is enhanced when blood flow is slow and the cells are tightly packed: both of these conditions are found in the alveolar capillaries.

Within the erythrocytes the merozoites grow first to a ring-shaped form and then to a larger [trophozoite](#) form. In the [schizont](#) stage, the parasite divides several times to produce new merozoites, which leave the red blood cells and travel within the

bloodstream to invade new red blood cells. Most merozoites continue this replicative cycle, but some merozoites differentiate into male or female sexual forms ([gametocytes](#)) (also in the blood), which are taken up by the female mosquito.

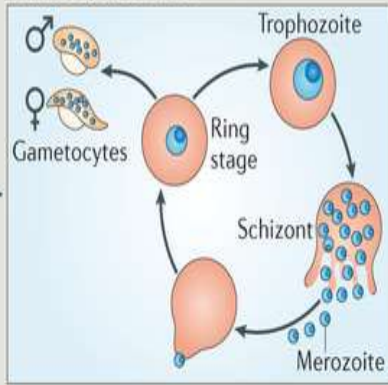
In the mosquito's midgut, the [gametocytes](#) develop into [gametes](#) and [fertilize](#) each other, forming a [zygote](#). After a brief period of inactivity, zygotes transform into a motile form called [ookinetes](#). The ookinetes penetrate and escape the midgut, then embed themselves onto the exterior of the gut membrane and transform into oocysts. The nuclei of oocysts divide many times to produce large numbers of tiny elongated [sporozoites](#). These sporozoites migrate to the salivary glands of the mosquito where they are injected into the blood of the next host the mosquito bites. The sporozoites move to the liver where they repeat the cycle.

The pattern of alternation of sexual and asexual reproduction is common in parasitic species. The evolutionary advantages of this type of life cycle were recognised by [Mendel](#). Under favourable conditions, asexual reproduction is superior to sexual as the parent is well adapted to its environment and its descendents share all its genes. Transferring to a new host or in times of stress, sexual reproduction is generally superior as it shuffles the [genes](#) of two parents, producing a variety of individuals, some of which will be better adapted to the new environment.

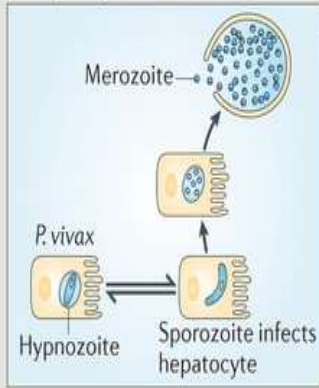
Reactivation of the hypnozoites has been reported for up to 30 years after the initial infection in humans. The factors precipitating this reactivation are not known. In the species [Plasmodium malariae](#), [Plasmodium ovale](#) and [Plasmodium vivax](#) hypnozoites have been shown to occur. Reactivation does not occur in infections with [Plasmodium falciparum](#). It is not known if hypnozoite reactivation may occur with any of the remaining species that infect humans but this is presumed to be the case.

a Plasmodium life cycle

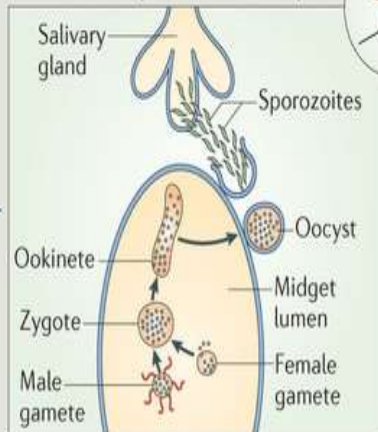
Asexual stage (bloodstream)
Parasite cycle in RBCs



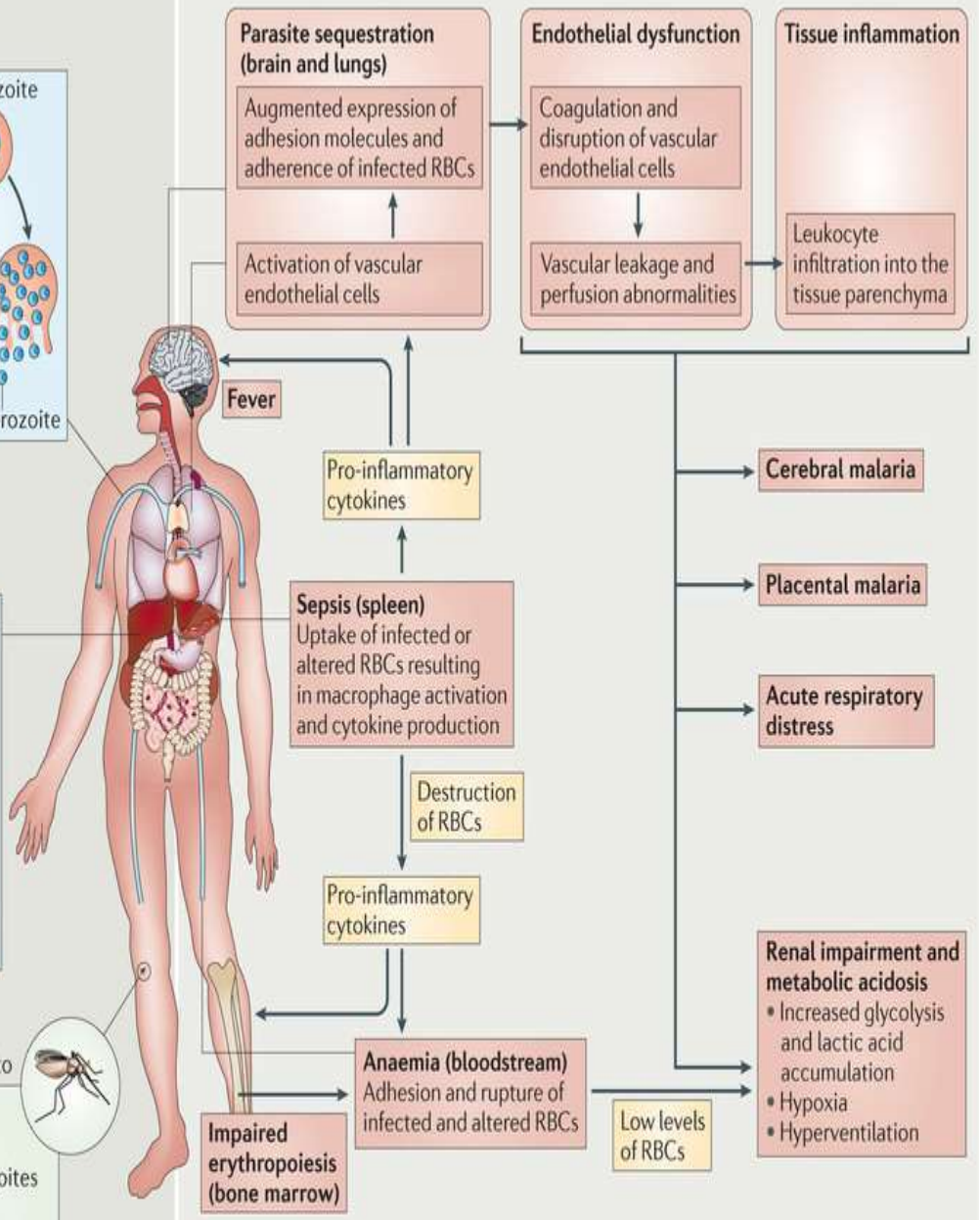
Asexual stage (liver)
Infection and parasite replication in hepatocytes



Sexual stage (mosquito)
Parasite development in the mosquito



b Pathogenesis of malaria



Phylum Platy helminthes

Class Trematoda

Trematoda is a class within the phylum Platyhelminthes. It includes two groups of parasitic flatworms, known as **flukes**.

They are internal parasites of molluscs and vertebrates. Most trematodes have a complex life cycle with at least two hosts. The primary host, where the flukes sexually reproduce, is a vertebrate. The intermediate host, in which asexual reproduction occurs, is usually a snail.

Trematodes are flattened oval or worm-like animals, usually no more than a few centimetres in length, although species as small as 1 millimetre (0.039 in) (Monogenea) (Monogenea is not under the class trematoda it is a separate class under platyhelminthes) and as large as 7 centimetres (2.8 in) (Fasciolopsis) are known. Their most distinctive external feature is the presence of two suckers, one close to the mouth, and the other on the underside of the animal.

The body surface of trematodes comprises a tough syncytial tegument, which helps protect against digestive enzymes in those species that inhabit the gut of larger animals. It is also the surface of gas exchange; there are no respiratory organs.

The mouth is located at the forward end of the animal, and opens into a muscular, pumping pharynx. The pharynx connects, via a short oesophagus, to one or two blind-ending caeca, which occupy most of the length of the body. In some species, the caeca are themselves branched. As in other flatworms, there is no anus, and waste material must be egested through the mouth.^[3]

Although the excretion of nitrogenous waste occurs mostly through the tegument, trematodes do possess an excretory system, which is instead mainly concerned with osmoregulation. This consists of two or more protonephridia, with those on each side of the body opening into a collecting duct. The two collecting ducts typically meet up at a single bladder, opening to the exterior through one or two pores near the posterior end of the animal.

The brain consists of a pair of ganglia in the head region, from which two or three pairs of nerve cords run down the length of the body. The nerve cords running along the ventral surface are always the largest, while the dorsal cords are present only in the Aspidogastrea. Trematodes generally lack any specialised sense organs, although some ectoparasitic species do possess one or two pairs of simple ocelli.

Life cycle

Trematodes have a large variation of forms throughout their life cycles. Individual trematode parasites life cycles may vary from this list.

1. Trematodes are released from the definitive host as eggs, which have evolved to withstand the harsh environment
2. Released from the egg is the miracidium. This infects the first intermediate host in one of two ways, either active or passive transmission. a) Active transmission has adapted for dispersal in space as a free swimming ciliated miracidium with adaptations for recognising and penetrating the first intermediate host. b) Passive transmission has adapted for dispersal in time and infects the first intermediate host contained within the egg.
3. The sporocyst forms inside the snail first intermediate host and feeds through diffusion across the tegument
4. The rediae also forms inside the snail first intermediate host and feeds through a developed pharynx. Either the rediae or the sporocyst develops into the cercariae through polyembryony in the snail.
5. The cercariae are adapted for dispersal in space and exhibit a large variety in morphology. They are adapted to recognise and penetrate the second intermediate host, and contain behavioural and physiological adaptations not present in earlier life stages.
6. The metacercariae are an adapted cystic form dormant in the secondary intermediate host.
7. The adult is the fully developed form which infects the definitive host.

TREMATODES FLUKES •

The most significant trematodes from a clinical point of view are • bloodflukes, *Schistosoma mansoni*, *S. japonicum* and *S. hematobium*. Other trematodes of significance are intestinal fluke, *Fasciolopsis buski*, liver fluke, *Clonorchis sinensis* and lung fluke, *Paragonimus westermani*.

Blood fluke

Schistosomiasis (Bilharziasis) •

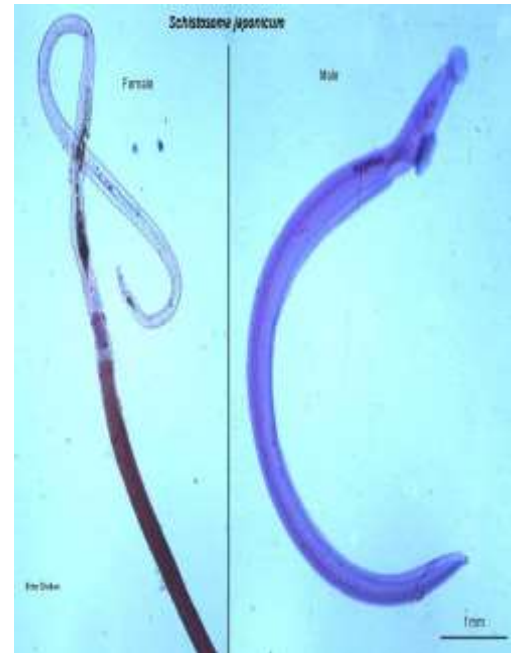
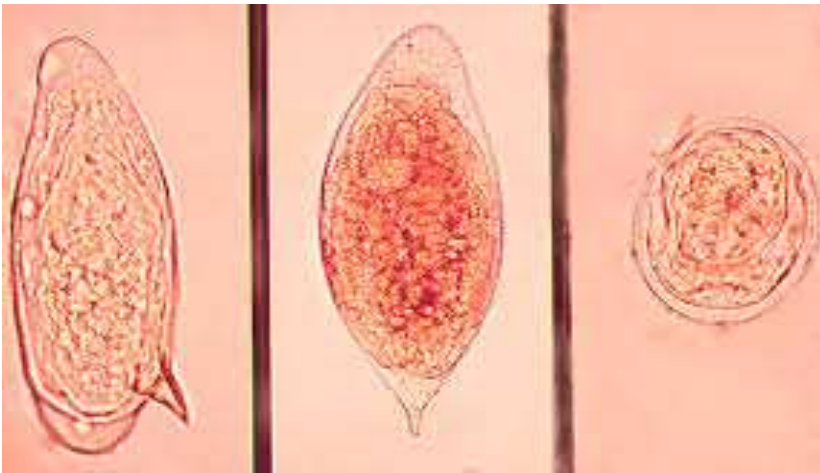
The three species of *Schistosoma* have different geographic • distributions. *S. hematobium* is prevalent in Africa, *S. mansoni* is found in Africa and America and *S. japonicum* is common in the far east.

Epidemiology •

Approximately 250 million people are infected with schistosomes and 600 million are at risk.

Morphology •

Adult worms are 10 to 20 mm long; the male has an unusual lamelliform shape with marginal folds forming a canal in which the slender female worm resides. Unlike other trematodes, schistosomes have separate sexes



Unlike all other trematodes, schistosomes are not hermaphroditic but dioecious, forming separate sexes. Adult worms have elongate tubular bodies, each male having a unique gynecophoral canal (schisto-soma = split body) in which a female worm resides. They live inside visceral blood vessels and are commonly known as blood flukes. They have digenetic life-cycles involving aquatic snails as obligate intermediate hosts. Eggs deposited in the circulation penetrate the gut or bladder to be excreted with faeces or urine. In water, the eggs release miracidia which infect snails and undergo asexual proliferation through sporocyst stages eventually releasing cercariae back into the water. Vertebrate hosts become infected by direct penetration of the skin. Infections may cause chronic debilitating diseases in humans and some domestic animals.

***Schistosoma* spp.** [these species cause schistosomiasis/bilharzia in humans and ruminants]

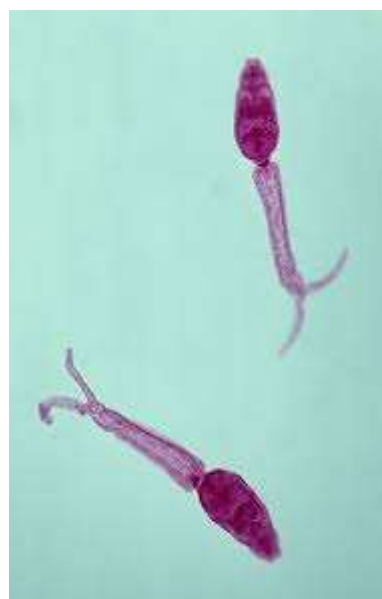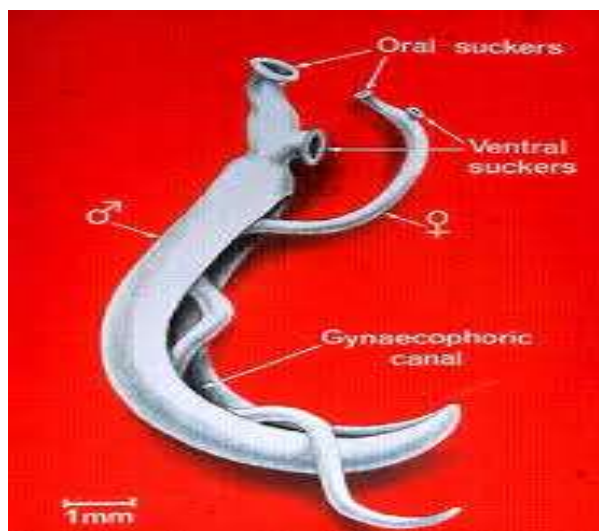
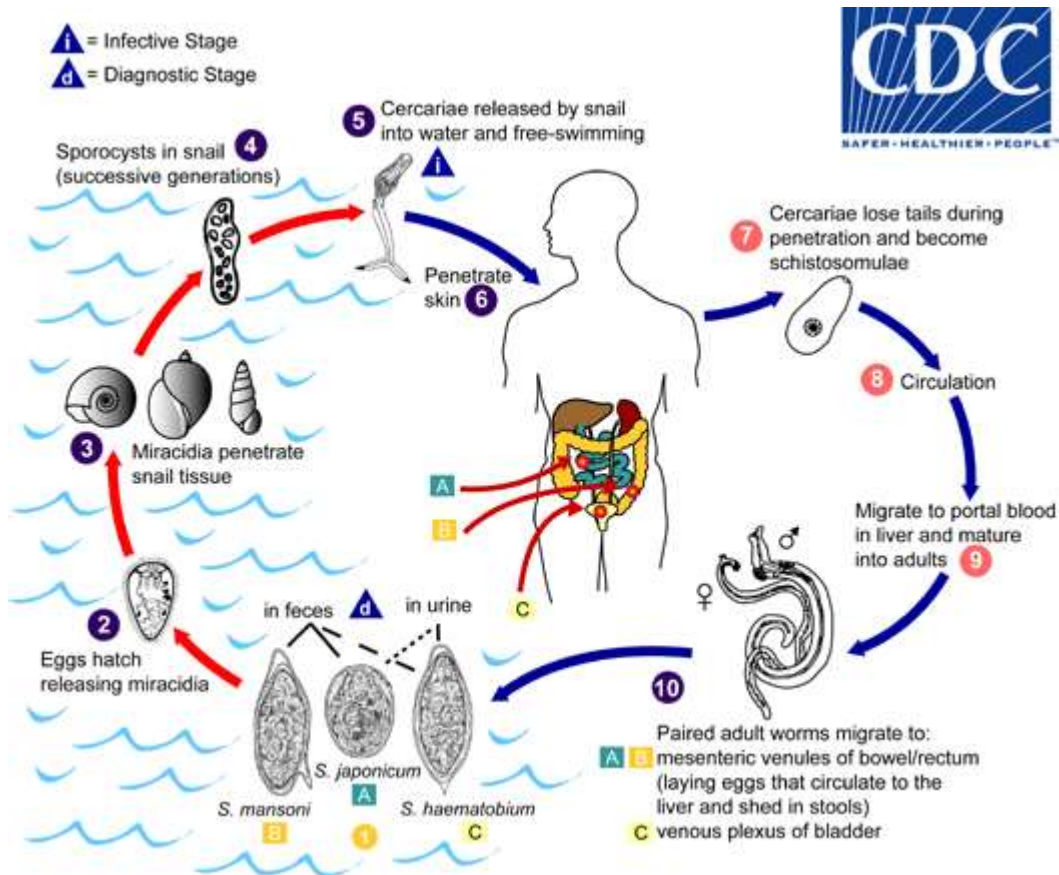
Parasite morphology: Blood flukes form five different developmental stages: •
eggs, miracidia, sporocysts, cercariae and adult worms. Eggs are round to oval in shape, operculate (hinged at one end) and contain a developing embryonic larva (miracidium). Differences in egg morphology can be used to distinguish

between *Schistosoma* species: *S. mansoni* producing oval eggs (115-175 x 45-70µm) with a sharp lateral spine, *S. japonicum* forming round eggs (70-100 x 50-70µm) with a rudimentary lateral spine; and *S. haematobium* producing oval eggs (110-170 x 40-70µm) with a sharp terminal spine. Miracidia are elliptical free-swimming larval stages (~200µm long) covered with cilia. Sporocysts appear as pleomorphic sac-like bodies which contain developing cercariae. Mature cercariae are elongate free-swimming larval stages (400-600µm long) consisting of a tapering head (with prominent penetration glands) and a forked tail (furcocercous). Adult flukes are elongate tubular worms (10-20mm long), with rudimentary oral and ventral suckers. Males are shorter and stouter than females, and they have a longitudinal cleft (gynecophoral canal or schist) in which the longer slender female lies folded.

Life cycle of schistosom

Eggs are eliminated with feces or urine . Under optimal conditions the eggs hatch and release miracidia , which swim and penetrate specific snail intermediate hosts . The stages in the snail include 2 generations of sporocysts and the production of cercariae . Upon release from the snail, the infective cercariae swim, penetrate the skin of the human host , and shed their forked tail, becoming schistosomulae .

The schistosomulae migrate through several tissues and stages to their residence in the veins. Adult worms in humans reside in the mesenteric venules in various locations, which at times seem to be specific for each species. For instance, *S. japonicum* is more frequently found in the superior mesenteric veins draining the small intestine (A), and *S. mansoni* occurs more often in the inferior mesenteric veins draining the large intestine(B) .However, both species can occupy either location, and they are capable of moving between sites, so it is not possible to state unequivocally that one species only occurs in one location. *S. haematobium* most often occurs in the venous plexus of bladder(C) , but it can also be found in the rectal venules. The females (size 7 to 20 mm; males slightly smaller) deposit eggs in the small venules of the portal and perivesical systems



Symptoms

Penetration of cercariae causes transient dermatitis (swimmers' itch). The symptoms of schistosomiasis are primarily due to a reaction against the eggs and include splenomegaly, lymphadenopathy and diarrhea. In the bladder, they produce granulomatous lesions, hematuria and

sometimes urethral occlusion. Most bladder cancers in endemic areas are associated with chronic infection. In the intestine, they cause polyp formation which, in severe cases, may result in life threatening dysentery.

In the liver, the eggs cause periportal fibrosis and portal hypertension • resulting in hepatomegaly, splenomegaly and ascites. A gross enlargement of the esophageal and gastric veins may result in their rupture. *S. japonicum* eggs are sometimes carried to the central nervous system and cause headache, disorientation, amnesia and coma. Eggs carried to the heart produce arteriolitis and fibrosis resulting in enlargement and failure of the right ventricle

Diagnosis •

Diagnosis is based on a history of residence in an endemic area, swimmers' itch and other symptoms. The eggs are very characteristic and confirm diagnosis. *S. hematobium* eggs in urine (55 to 65 by 110 to 170 micrometers) have an apical spine or knob. *S. mansoni* eggs in feces (45 to 70 by 115-175 micrometers) have a spine on the side. *S. japonicum* eggs (55 to 65 by 70 to 100 micrometers) are more round with a vague spine on the side.

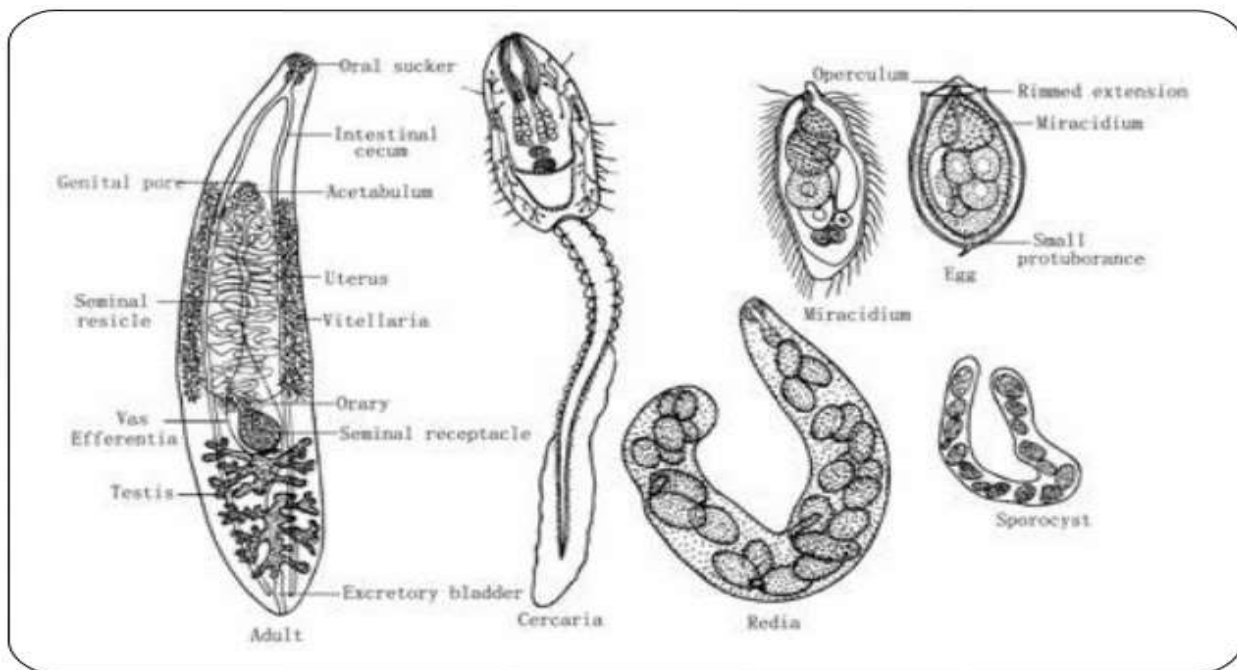
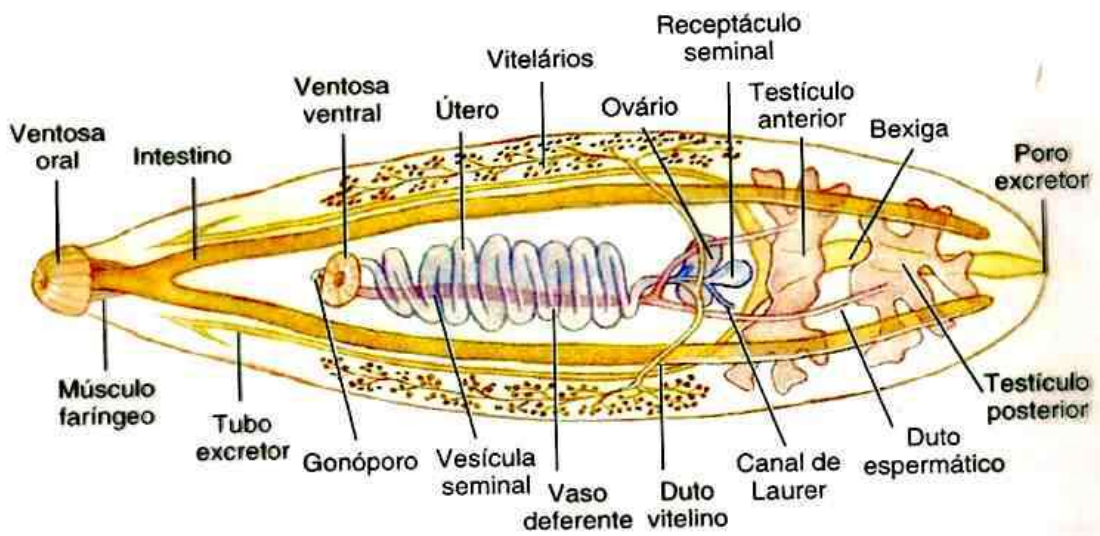
***Clonorchis sinensis* (Chinese Liver Fluke)** •

Epidemiology •

This is a widespread parasite of man, dogs and cats in the southeast of Asia. It is extraordinarily common in China and is also found in Korea and Japan. Related flukes parasitizing European cats (*Opisthorchis felinus*) and dogs (*O. viverrini*) infect humans in the endemic areas.

Morphology •

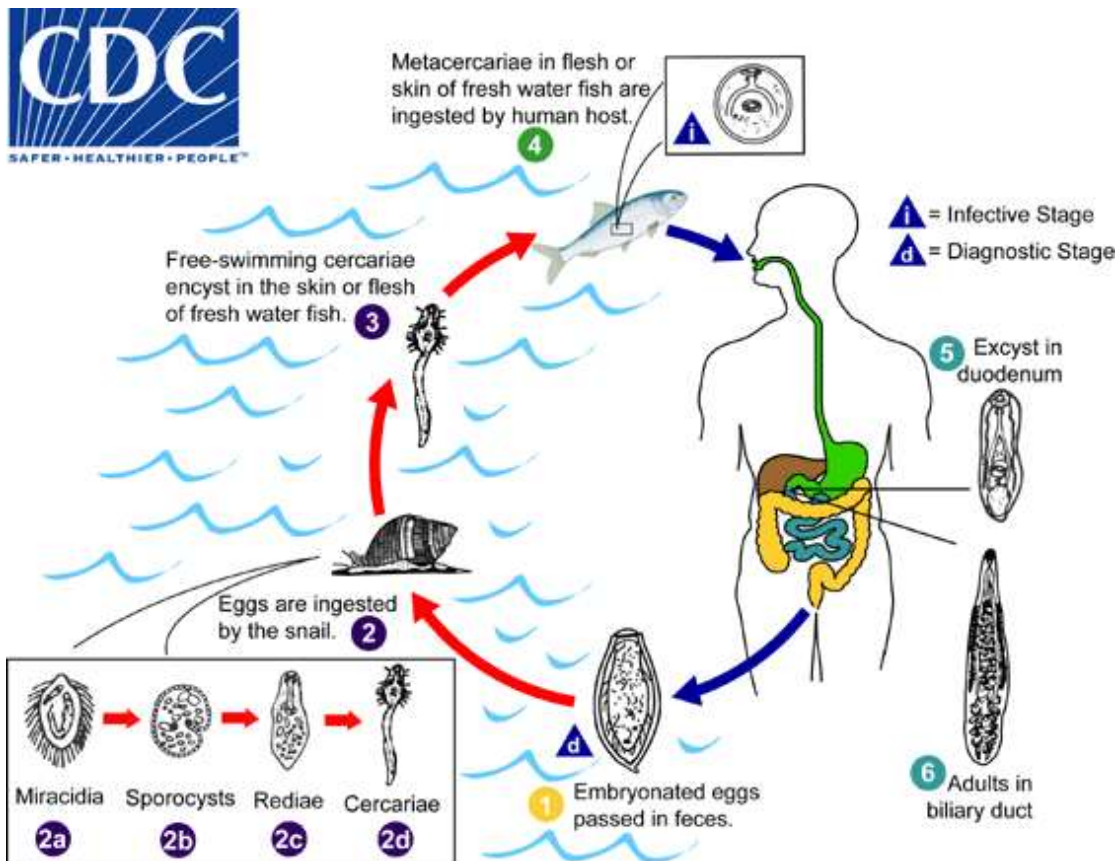
These are spindloid flukes measuring about 16 by 4 mm. The eggs measure 29 by 16 micrometers



Life cycle •

Man is infected by eating raw or improperly cooked fish which carries the infective metacercaria in a cyst. The cyst is digested and the larval worm migrates up the bile duct to the liver where it matures into an adult. The eggs, deposited in the biliary duct, pass in the feces and find their way to fresh water. Upon ingestion by a suitable fresh water

operculate snail, the egg hatches to produce a miracidium. The miracidium in the snail develops into cercaria which breaks out in water to penetrate under the scales of fish. In fish, the cercaria encysts in the muscle and forms metacercariae infectious to man



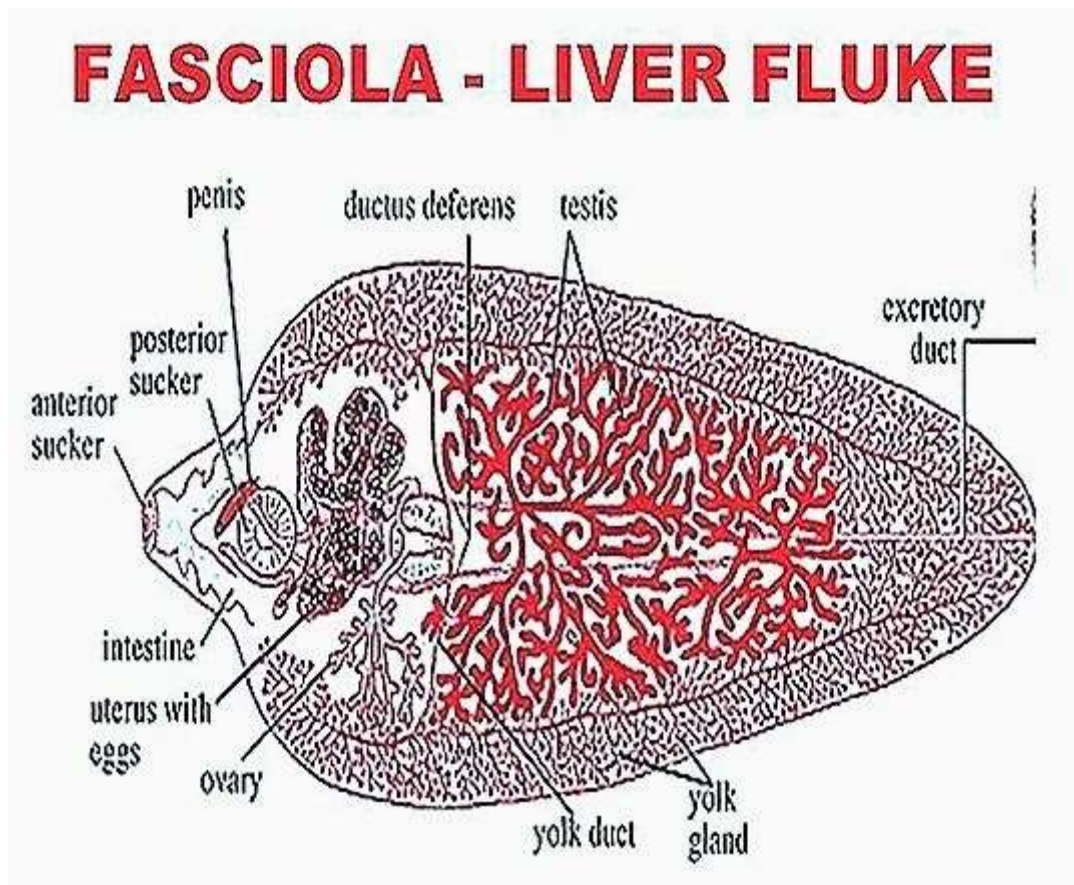
Symptoms •

The worm causes irritation of the bile ducts which become dilated and deviated. The liver may enlarge, become necrotic and tender and its function may be impaired. Modest infections results in indigestion, epigastric discomfort, weakness and loss of weight. Heavier infections produce anemia, liver enlargement, slight jaundice, edema, ascites and diarrhea.

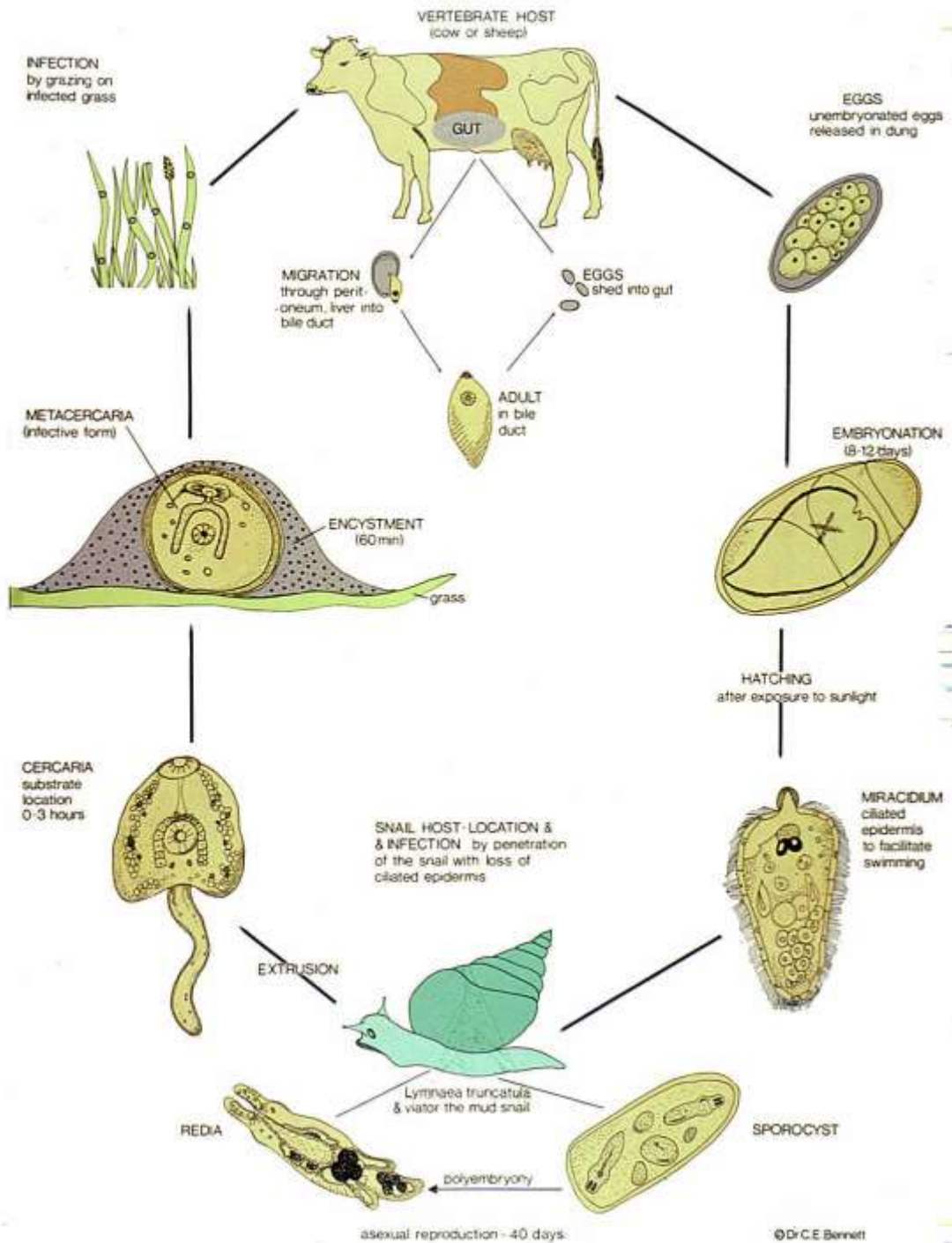
- **Fascioliasis**

- Fascioliasis is a parasitic infection typically caused by *Fasciola hepatica*, which is also known as "the common liver fluke" or "the sheep liver fluke." A related parasite, *Fasciola gigantica*, also can infect people. Fascioliasis is found in all 5 continents, in over 50 countries, especially where sheep or cattle are reared. People usually become infected by eating raw watercress or other water plants contaminated with immature parasite larvae. The immature larval flukes migrate through the intestinal wall, the abdominal cavity, and the liver tissue, into the bile ducts, where they develop into mature adult flukes, which produce eggs. The pathology typically is most pronounced in the bile ducts and liver. *Fasciola* infection is both treatable and preventable.
- *Fasciola hepatica* egg in an unstained wet mount (400x magnification). *F. hepatica* eggs are broadly ellipsoidal, operculated, and measure 130-150 µm by 60-90 µm. Center: Adult *Fasciola hepatica* fluke stained with carmine (30 mm by 13 mm). Right: *Fossaria bulamoides*, a snail host for *F. hepatica* in the western United States. Credit: [DPDx](#), Conchology, Inc, Mactan Island, Philippines.
- **disease**
- Human fascioliasis is usually recognized as an infection of the bile ducts and liver, but infection in other parts of the body can occur.
- In the early (acute) phase, symptoms can occur as a result of the parasite's migration from the intestine to and through the liver. Symptoms can include gastrointestinal problems such as nausea, vomiting, and abdominal pain/tenderness. Fever, rash, and difficulty breathing may occur.
- During the chronic phase (after the parasite settles in the bile ducts), the clinical manifestations may be similar or more discrete, reflecting inflammation and blockage of bile ducts, which can be intermittent. Inflammation of the liver, gallbladder, and pancreas also can occur.
- **Diagnosis**
- The standard way to be sure a person is infected with *Fasciola* is by seeing the parasite. This is usually done by finding *Fasciola* eggs in stool (fecal) specimens examined under a microscope. More than one specimen may need to be examined to find the parasite. Sometimes eggs are found by examining duodenal contents or bile.
- Infected people don't start passing eggs until they have been infected for several months; people don't pass eggs during the acute phase of the infection. Therefore, early on, the infection has to be diagnosed in other ways than by examining stool. Even during the chronic phase of infection, it can be difficult to find eggs in stool specimens from people who have light infections.

- Certain types of blood tests can be helpful for diagnosing *Fasciola* infection, including routine blood work and tests that detect antibodies (an immune response) to the parasite.



The Life Cycle of *Fasciola hepatica*.



Paragonimus Westermani - Lung Fluke

Human lung fluke, *Paragonimus westermani*, infects 22 million people in Africa, Asia and South and Central America. Southeast Asia in particular is affected because raw seafood is very popular there. Humans get infected with the disease, paragonimiasis, by eating raw crabs or fish that are carrying the parasite. Even properly cooked sushi can cause infection, if the cook or waiter is careless when preparing the food. In Asia about 80 % of freshwater crabs are infected with the lung fluke.

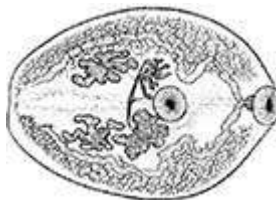
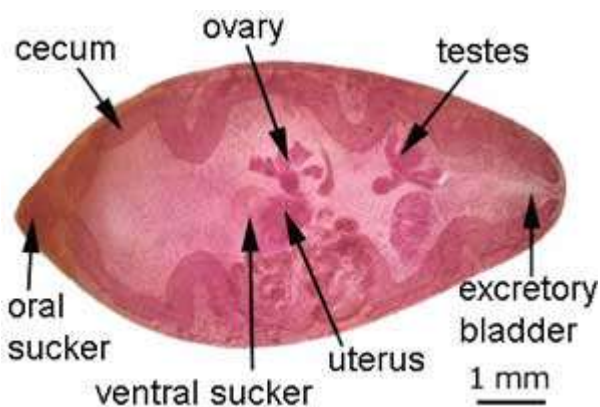
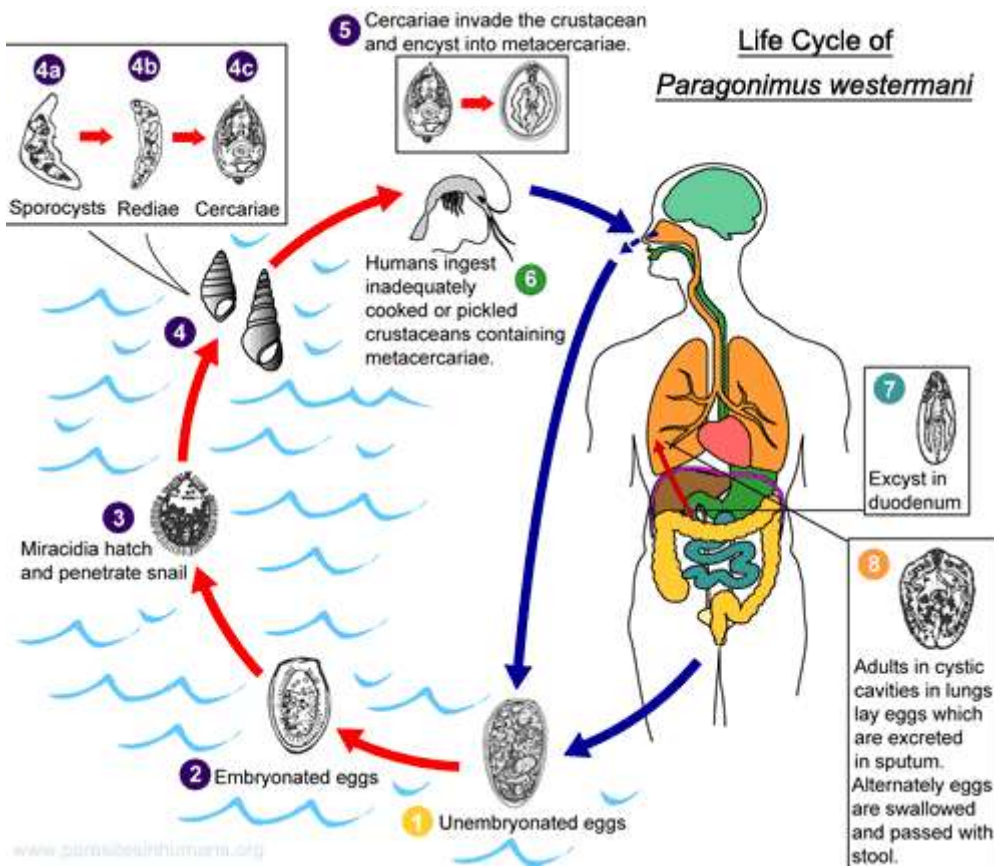
Life cycle

of a lung fluke begins, when worm lays eggs that are carried out from the human lungs in the sputum by the motion of microvilli. Then the eggs are taken through the gastrointestinal tract and out of the body. If the feces get in contact with water, then after two weeks larvae called miracidia hatch and start to grow. A miracidium finds a snail and penetrates its skin. In 3–5 months miracidium develops further and produces another larval form called cercaria. The cercaria crawls out of the snail to find fresh water crayfish (a lobster-like creature) or crabs. It finds its way to the muscles of the crab and starts forming a cyst. Within two months it transforms into metacercaria which is the resting form of cercaria. If a human eats this infected crab raw, the metacercaria cyst gets into the stomach. Once inside the beginning of the small intestine, duodenum, the metacercaria excysts and penetrates the intestinal wall. It continues through abdominal wall and diaphragm into the lungs where it forms a capsule and develops into an adult. Male and female lung worms reproduce and the cycle starts again.

Sometimes lung fluke larvae accidentally travel to the brain or other organs and reproduce there. But because the secretion of the eggs from the brain is blocked the life cycle will not happen. If the worm goes to the spinal cord instead of the lungs, the host might become paralyzed. If it infects the heart, the host could die.

Lung flukes cause **pain** and severe **coughing** (there might be some blood, too). Paragonimiasis **diagnosis** is done by looking at sputum (slime from the lungs), to see if there are any lung fluke eggs. Feces can be examined, too. Alternatively X-rays and biopsies can be taken. Paragonimiasis is usually **treated** with a drug called praziquantel.

Salting food does not kill the parasite, cooking and freezing will. After ingestion it takes about three months for the lung fluke to start laying eggs. The host might stay infected up to 20 years.



Adult lung flukes are 4–6 mm wide, 3–5 mm thick and 7–12 mm long. They are red-brown looking almost like a coffee bean. They hold on to tissue with two suckers. The oral sucker is in the front and just before the center of its lower body is the ventral sucker.

In addition to humans, *Paragonimus westermani* infects other carnivores such as felids (cats etc.), canids (dogs etc.), rodents (rats etc.), weasels and pigs.

Clinical Presentation

The acute phase (invasion and migration) may be marked by diarrhea, abdominal pain, fever, cough, urticaria, hepatosplenomegaly, pulmonary abnormalities, and eosinophilia. During the chronic phase, pulmonary manifestations include cough, expectoration of discolored sputum, hemoptysis, and chest radiographic abnormalities. Extrapulmonary locations of the adult worms result in more severe manifestations, especially when the brain is involved.

Minute teardrop-shaped flukes found in the small intestines of fish-eating birds and mammals. The eggs are hard to tell apart from other related species so there is no accurate estimate of human infection. The adult flukes range from 1.1 mm to 1.7 mm long and about 0.35 mm at their greatest width. The body of the fluke is covered in scales mostly concentrated at the anterior end. Also at the anterior end is an oral sucker. Located in the medioanterior of the body is the acetabulum. At the posterior end of the fluke are two oval testes. The vas deferens leading from the testes expands to form a seminal vesicle and then narrows again to form an ejaculatory duct. The fluke also has female reproductive organs. Located medioposterior is the fluke's one ovary and leading away from the ovary is the vitellaria. The uterus is a long tube like structure that also leads away from the ovary and joins up with the ejaculatory duct to form the genital duct which leads to a genital sinus. The sinus leads to the genital pore which is lined with 60-90 toothed spines. When a *H. heterophyes* was taken out of a man and then looked at the ultrastructures on the tegument it was described to have spines that looked like a round comb.^[4] The genital pore is where the fluke releases its eggs. *H. heterophyes* will also have morphological differences based on the different fishes that it inhabited

Morphology of Adult *Heterophyes*

Adults are small, less than 2 mm in length.

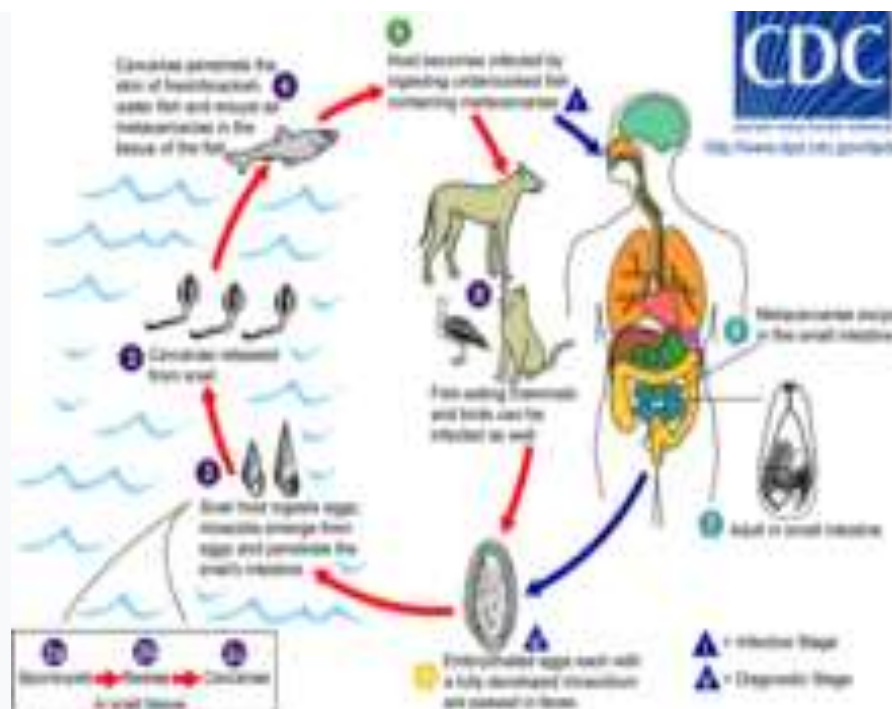
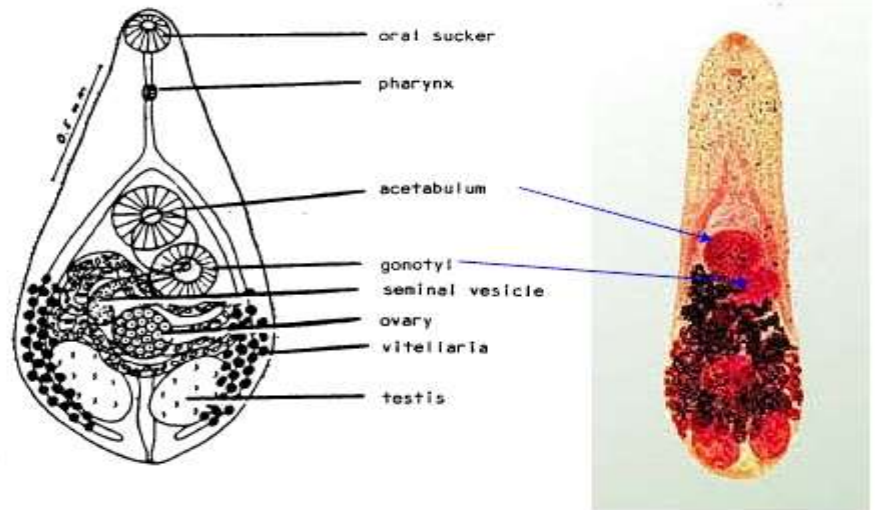
Characteristic structure is the

_____ ,
a muscular and spinous sucker surrounding the common genital pore.

Gonotyl is located near acetabulum.

Ovary is anterior to testes.

Testes are opposite and posterior.



Life cycle of *Heterophyes heterophyes*.

The adult flukes live burrowed between the villi of the host's small intestine. It only takes around 4 to 6 hours for *H. heterophyes* to get to the small intestines in the definitive host and even faster in hosts that it does not prefer. The eggs that are laid contain a miracidium but do not hatch until they are ingested by a snail. Inside the snail's gut, the miracidium becomes a sporocyst which then begins to produce rediae. The rediae produce cercariae which then exit the snail, swim toward the surface of the water, and slowly fall back down. On their way down, they contact a fish and penetrate into the epithelium of the fish. Here, the cercariae encyst in the muscle tissue. The second intermediate host includes freshwater fish: *Mugil cephalus*, *Tilapia nilotica*, *Aphanius fasciatus*, and *Acanthogobius* sp. The definitive host, such as humans or birds, eats the undercooked or raw meat of a fish and ingests the parasite. Natural definitive hosts are cats, dogs, foxes, wolves, pelicans, and humans.

Pathology

Heterophyiasis

Each worm causes a mild inflammatory reaction at its site of contact with the intestine. In heavy infections which are common, cause damage to the mucosa and produce intestinal pain and mucosa diarrhea. Sometimes eggs can enter the blood and lymph vascular systems through mucosa go into the ectopic sites in the body. The heart can be affected with tissue reaction in the valves and myocardium that cause heart failure. Eggs can also get into the brain or spinal cord and cause neurological disorders and sometimes fatalities. Antigen and immune complex deposits left by *H. heterophyes* in the brain and kidneys of mice prove that there are changes in these tissues of the infected.

Diagnosis done by stool examination is difficult when adult worms are not present because the eggs are hard to distinguish from *C. sinensis*.

Class Cestoda

CESTODES (TAPE WORMS)

Clinically important cestodes pathogenic to man are *Tenia solium* (pork tapeworm), *T. saginata* (beef tapeworm), *Diphyllobothrium latum* (fish or broad tapeworm), *Hymenolepis nana* (dwarf tapeworm) and *Echinococcus granulosus* and *E. multilocularis* (hydatid).

Tenia solium or *T. saginata* (Teniasis)

Epidemiology: Worldwide distribution, higher in developing countries: as low as 1/1000 in most North America and as high as 10% in the 3rd world. Pork tapeworm incidence higher, depending on dietary habits.

Morphology: *T. saginata*: 4-6 meters long and 12 mm broad; pear-shaped (head) scolex with four suckers but no hooks, neck, and long flat body with several hundred segments (proglottids), 18x6 mm

each with branched uterus (15-30 branches). Roundish 35x45 μ yellow-brown egg has peripheral radial striations and contains an embryo with 3 hooklets (figure 2).

T. solium: Slightly smaller than *T. saginata*; globular scolex with four suckers and a circular row of hooks (rostellum) that gives it a solar appearance; neck, long flat body (0.1 meter); proglottids 5x10 mm with 7-12 branch uterus. Eggs are not distinguishable.

Life cycle: Tapeworm larval cyst (cysticercus) is ingested with poorly cooked infected meat, the larva escapes the cyst and passes to the small intestine where it attaches to the mucosa by the scolex suckers. The proglottids develop as the worm matures in 3-4 months. The adult may live in the small intestine as long as 25 years and pass gravid proglottids with feces. Eggs extruded from the proglottid contaminate and persist on vegetation for several days and are consumed by cattle or pigs in which they hatch and form cysticerci .

Symptoms: Light infections remain asymptomatic, but heavier infections may produce abdominal discomfort, epigastric pain, vomiting and diarrhea.

Cysticercosis: *T. solium* eggs can also infect humans and cause cysticercosis (larval cysts in lung, liver, eye and brain) resulting in blindness and neurological disorders. The incidence of cerebral cysticercosis can be as high 1/1000 and may account for up to 20% of neurological case in some countries (e.g., Mexico); ocular cysticercosis is 2.5% and muscular involvement is as high as 10% (India).

Pathology and Immunology: Gastrointestinal symptoms are due to the presence of the tape worm. Cysticercosis symptoms are a result of inflammatory/immune responses. Antibodies are produced in cysticercosis and are useful epidemiological tools.

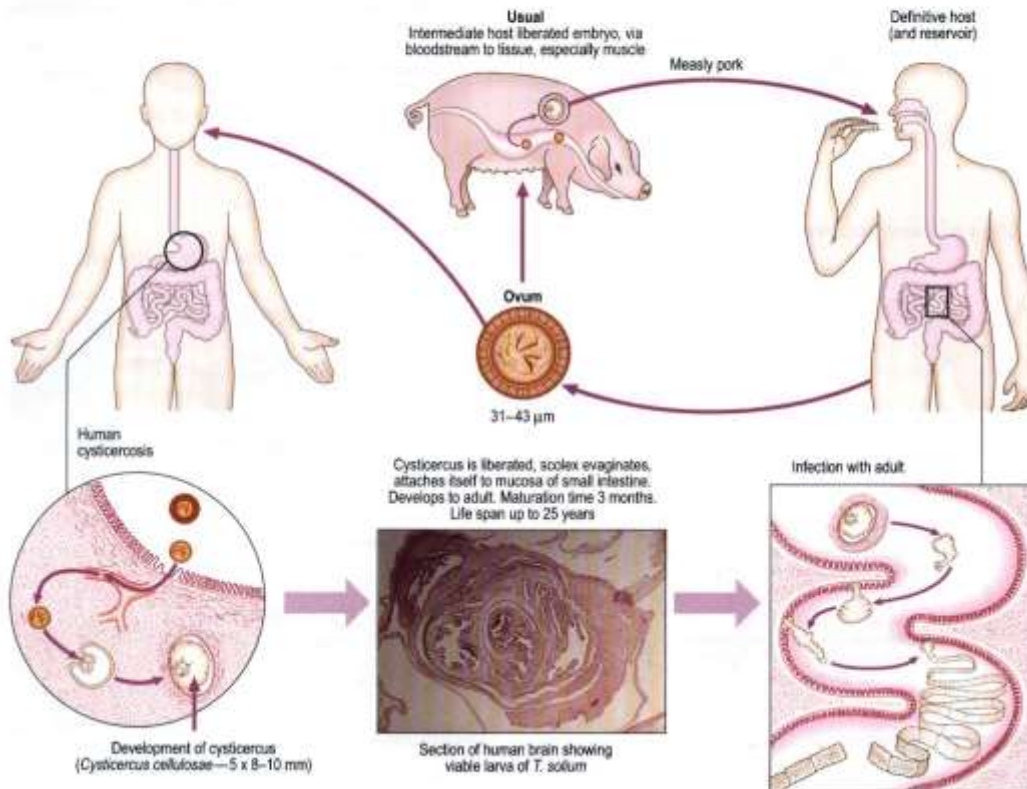
Diagnosis: Diagnosis is based on the recovery of eggs or proglottids in stool or from the perianal area. Cysticercosis is confirmed by the presence of antibodies.

Treatment and control: Praziquantel is the drug of choice. Expulsion of scolex must be assured to assume a satisfactory treatment. A thorough inspection of beef and pork, adequate cooking or freezing of meat are effective precautions, since cysticerci do not survive temperatures below -10° C and above

Cestode (tape) worms

Taenia solium (pork tape worm)

Life cycle



Pathology and Clinical features

Infection by larvae (cysticercosis). Cysticerci, generally multiple, may occur in any site but are more frequent in the brain and muscle. They excite reaction in the area, especially when they die, which manifests as inflammation, fibrosis and later some calcification. This leads to focal CNS syndromes, especially epilepsy.

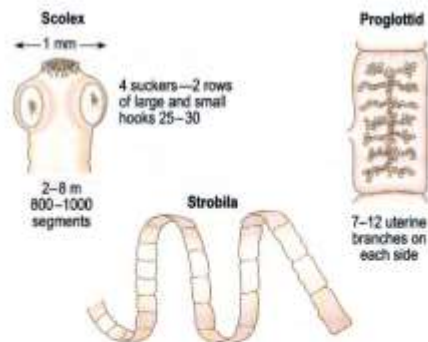
Infection with adults. Often there can be no pathology, but there might be mild irritation of intestinal mucosa.

Laboratory diagnosis

Eosinophilia.

Larval infections. There are several methods, including histological examination of biopsy material, serology (IFAT, ELISA, EITB) and radiology (CT or MRI scan of the brain, X-ray of the thigh muscles).

Pure infection with the adult. Gravid segments, ova and scolex can be found in faeces. The uterine branches of the mature segments can be demonstrated by injection of Indian ink through the uterine pore.

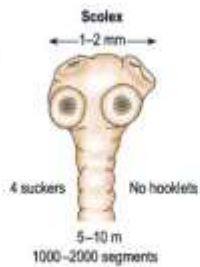
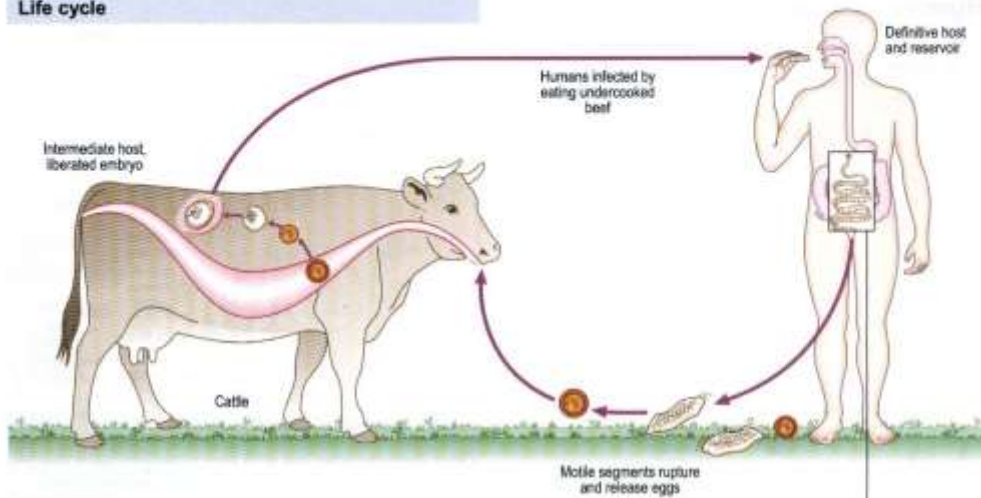


Distribution

5 million people infected worldwide. *Taenia solium* is endemic in pig-rearing areas of the world where hygiene and animal husbandry are poor.

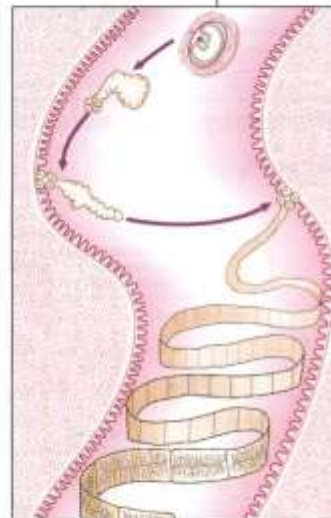
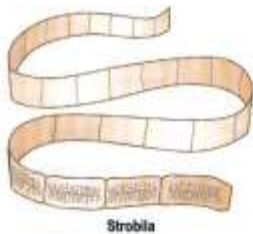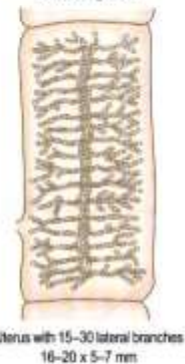Taenia saginata (beef tape worm)

Life cycle



Scolex evaginates in small intestine and attaches itself to mucosa of jejunum

Gravid segment



Maturation time 8-10 weeks
Life span up to 25 years

Pathology and Clinical features

Usually there is no pathology as *Cysticercus bovis* is unknown in humans. Occasionally there is vague alimentary upset.

Laboratory diagnosis

Gravid segments, ova and scolex can be found in faeces. Uterine branches of the mature segments may be seen in a crush preparation between two glass slides, or by Indian ink preparation, as in *T. solium*. Ova are also found on the perianal skin (on clear adhesive tape slides).

Distribution

Taenia saginata is found in beef-eating areas, especially in the tropics.

Echinococcus granulosus

Epidemiology: The organism is common in Asia, Australia, Eastern Africa, southern Spain, southern parts of South America and northern parts of North America. The incidence of human infection about 1-2/1000 and may be higher in rural areas of affected regions.

Morphology: This is the smallest of all tapeworms (3-9 mm long) with only 3 proglottids.

Life cycle: The adult worm lives in domestic and wild carnivorous animals. Eggs, passed by infected animals, are ingested by the grazing farm animals or man, localize in different organs and develop into hydatid cysts containing many larvae (proto-scolices or hydatid sand) (Figure 8). When other animals consume infected organs of these animals, proto-scolices escape the cyst, enter the small intestine and develop into adult worms (Figure 7). Echinococcus eggs, when swallowed by man, produce embryos that penetrate small intestine, enter circulation and form cysts in liver, lung, bones, and sometimes, brain. The cyst is round and measures 1-7 cm. in diameter, although it may grow to be 30 cm. The cyst consists of an outer anuclear hyaline cuticula, an inner nucleated germinal layer containing clear yellow fluid. Attached to the germinal layer, there are daughter cysts although some cysts, known as brood cysts, may only have hydatid sand. Man is a dead end host.

Symptoms: The symptoms, comparable to those of a slowly growing tumor, depend upon the location of the cyst. Abdominal cysts, when large produce increasing discomfort. Liver cysts cause obstructive jaundice. Peribronchial cysts may produce pulmonary abscess. Brain cysts produce intracranial pressure and Jacksonian epilepsy. Kidney cysts cause renal dysfunction. Contents of cyst produce anaphylactic responses.

Diagnosis: Clinical symptoms of a slow-growing tumor accompanied by eosinophilia are suggestive. Intradermal (Casoni) test with hydatid fluid is useful. Pulmonary cysts and calcified cysts can be visualized by x-ray. Antibodies against hydatid fluid antigens have been detected in a sizable population of infected individuals by ELISA or indirect hemagglutination test.

Treatment and control: Treatment involves surgical removal of cyst or inactivation of hydatid sand by injecting the cyst with 10% formalin and its removal within 5 minutes. High dose of Mebendazole have claimed some success. Preventive measure involve avoiding contact with infected dogs and cats and elimination of their infection.

Echinococcus granulosus

Epidemiology: The organism is common in Asia, Australia, Eastern Africa, southern Spain, southern parts of South America and northern parts of North America. The incidence of human infection about 1-2/1000 and may be higher in rural areas of affected regions.

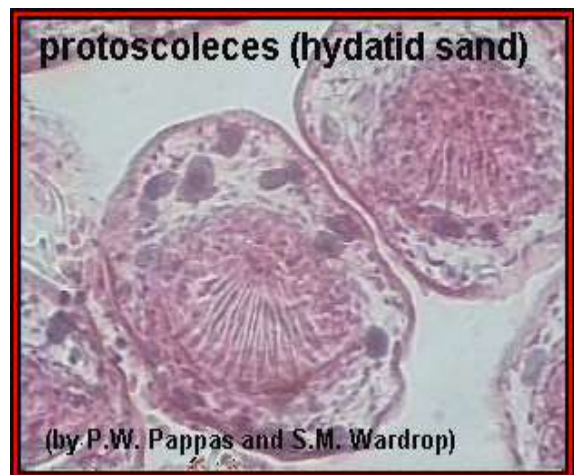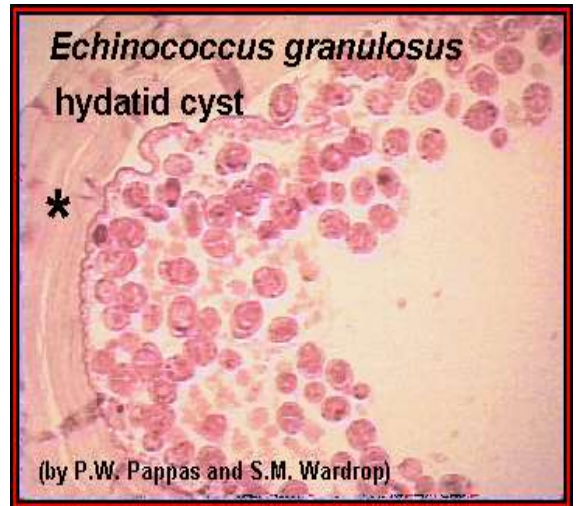
Morphology: This is the smallest of all tapeworms (3-9 mm long) with only 3 proglottids.

Life cycle: The adult worm lives in domestic and wild carnivorous animals. Eggs, passed by infected animals, are ingested by the grazing farm animals or man, localize in different organs and develop into hydatid cysts containing many larvae (proto-scolices or hydatid sand) (Figure 8). When other animals consume infected organs of these animals, proto-scolices escape the cyst, enter the small intestine and develop into adult worms (Figure 7). *Echinococcus* eggs, when swallowed by man, produce embryos that penetrate small intestine, enter circulation and form cysts in liver, lung, bones, and sometimes, brain. The cyst is round and measures 1-7 cm. in diameter, although it may grow to be 30 cm. The cyst consists of an outer anuclear hyaline cuticula, an inner nucleated germinal layer containing clear yellow fluid. Attached to the germinal layer, there are daughter cysts although some cysts, known as brood cysts, may only have hydatid sand. Man is a dead end host.

Symptoms: The symptoms, comparable to those of a slowly growing tumor, depend upon the location of the cyst. Abdominal cysts, when large produce increasing discomfort. Liver cysts cause obstructive jaundice. Peribronchial cysts may produce pulmonary abscess. Brain cysts produce intracranial pressure and Jacksonian epilepsy. Kidney cysts cause renal dysfunction. Contents of cyst produce anaphylactic responses.

Diagnosis: Clinical symptoms of a slow-growing tumor accompanied by eosinophilia are suggestive. Intradermal (Casoni) test with hydatid fluid is useful. Pulmonary cysts and calcified cysts can be visualized by x-ray. Antibodies against hydatid fluid antigens have been detected in a sizable population of infected individuals by ELISA or indirect hemagglutination test.

Treatment and control: Treatment involves surgical removal of cyst or inactivation of hydatid sand by injecting the cyst with 10% formalin and its removal within 5 minutes. High dose of Mebendazole have claimed some success. Preventive measure involve avoiding contact with infected dogs and cats and elimination of their infection.



Echinococcus granulosus (dog tape worm)

Life cycle

Echinococcus granulosus causes hydatid disease.

